

From the Department of Trauma and Orthopaedics

University of Lübeck

Director: Prof. Dr. med. Christian Jürgens

And

the Department of Anatomy

University of Lübeck

Director: Prof. Dr. med. Jürgen Westermann

**Biomechanical Comparison of Anterior Screw Fixation
Techniques for Type II Odontoid Fractures:
One- Versus Two-Screw Fixation**

Thesis

for

the acquisition of doctorate

at the University of Lübeck

- Medical Faculty -

presented by

Gang Feng

from Heilongjiang, China

Lübeck 2010

1. Berichterstatter: Priv.-Doz. Dr. med. Arndt-Peter Schulz

2. Berichterstatter: Priv.-Doz. Dr. med. Jan Philipp Benthien

Tag der mündlichen Prüfung: 6.9. 2011

zum Druck genehmigt. Lübeck, den 6.9. 2011

Table of contents

Abbreviations	6
I. Introduction	7
1.1 Incidence of Odontoid Fractures	7
1.2 Anatomy of the craniovertebral junction	7
1.3 Fracture Classification of Odontoid Fractures	9
1.4 Pathology and Pathophysiology of Odontoid Fractures	10
1.5 Treatment Options for Odontoid Fractures	11
1.6 Indications and Contraindications for Anterior Screw Fixation	14
1.6.1 Indications	14
1.6.2 Contraindications	14
1.7 Anterior Screw Fixation Technique	15
1.8 Controversial Discussion about Anterior Screw Fixation	16
1.9 Objectives of the Current Study	17
II. Materials and Methods	18
2.1 Materials	18
2.1.1 Specimens	18
2.1.2 Fracture Compression Screw (FCS)	18
2.1.3 Instrument Kit for Anterior Screw Fixation of Odontoid Fracture	18
2.1.4 Computer Tomography Machine	19
2.1.5 Embedding Resins	19
2.1.6 Biomechanical Testing Generic Block	19
2.1.7 Universal Mechanical Testing Machine (UTM)	20
2.1.8 Linear Variable Incremental-optical Displacement Transducer (LDT)	20
2.1.9 Optoelectronic Incremental Rotary Encoder	20
2.1.10 Torque Sensor	20
2.1.11 Self-designed and Custom-fit Devices	20
2.1.11.1 Rotational Testing Device (RTD)	20

2.1.11.2 <i>Spring Clamp</i>	21
2.1.12 Application Software	22
2.2 Subjects and Methods	22
2.2.1 Preliminary Experiments	22
2.2.1.1 Objective	22
2.2.1.2 Specimens Preparation	22
2.2.1.3 Testing Apparatus Setting	23
2.2.1.4 Study Procedure	25
2.2.1.5 Study Flow Chart of Preliminary Experiments.....	27
2.2.2 Main Experiments	27
2.2.2.1 Objective	27
2.2.2.2 Specimens Preparation	27
2.2.2.3 Testing Apparatus Setting	28
2.2.2.3.1 <i>Testing Shear Stiffness</i>	28
2.2.2.3.2 <i>Testing Torsional Stiffness</i>	28
2.2.2.4 The Definition of Studying Parameters	30
2.2.2.5 Study Procedure.....	30
2.2.2.5.1 <i>Step 1</i>	31
2.2.2.5.2 <i>Step 2</i>	31
2.2.2.6 Study Flow Chart of Main Experiments	34
2.2.3 Data Processing and Statistical Analysis	34
2.2.3.1 Data Processing	34
2.2.3.2 Statistical Analysis	35
III. Results	36
IV. Discussion	40
4.1 Literature Survey	40
4.2 Comparison of Own Research with Previous Research	41
4.2.1 The Torque Endured by the Odontoid in Normal Physiology Conditions	41
4.2.2 The influence of BMD	42

4.2.3 Screw Selected	43
4.2.4 The Design and the Method for Evaluation of the Stability in this Study ...	44
4.3 Critical Integration of Own Results and Conclusions	45
V. Summary	47
VI. References	48
VII. Attachments	53
VIII. Acknowledgements	56
IX. Curriculum Vitae	57

Abbreviations

BMD: Bone mineral density

C0: Occipital bone

C1: Atlas

C2: Axis

C0-C1: Occipito-atlantal unit

C1-C2: Atlanto-axial unit

C0-C1-C2: Occipito-atlanto-axial complex

CT: Computed tomography

FCS: Fracture compression screw

LDT: Linear variable incremental-optical displacement transducer

ROM: Range of motion

RTD: Rotational testing device

SA: Shear stiffness of odontoid loading from anterior

SCI: Spinal cord injury

SL: Shear stiffness of odontoid loading from left

SP: Shear stiffness of odontoid loading from posterior

SR: Shear stiffness of odontoid loading from right

TL: Torsional stiffness of odontoid in left rotation

TR: Torsional stiffness of odontoid in right rotation

UTM: Universal mechanical Testing Machine

I. Introduction

1.1 Incidence of Odontoid Fractures

The odontoid fracture is a common cervical spine injury and accounts for nearly 60% of all axis (C2) fractures and 5% to 17% of all cervical fractures.(14, 39-42, 80) Odontoid fractures occur in all age groups with a bimodal distribution.(13, 80, 82) The first peak is in young and middle aged. High-energy trauma, especially motor vehicle accident, is responsible for the majority of the odontoid injuries in this group. The second peak is in the elderly. In fact, odontoid fractures are the most common cervical spine fracture in patients older than 65 years old. These fractures, unlike those in the younger patients, tend to result from low energy injuries, such as falling from a standing height. The mechanism of injury often is hyperextension resulting in posterior displacement of the odontoid.(14, 20, 60, 71)

1.2 Anatomy of the craniovertebral junction

The craniovertebral junction, namely, the occipito-atlanto-axial complex (C0-C1-C2), is loosely, but stably, held together by an intricate arrangement of bony structures and ligaments. As a unique structure in several different ways compared to the lower cervical spine, the C0-C1-C2 allows extensive motion and yet remains capable of providing an amazingly three-dimensional stability.

Two joint units, the occipito-atlantal unit (C0-C1) and the atlanto-axial unit (C1-C2), are included in the C0-C1-C2 complex. The bony construction of the articulation at the C0-C1 level is composed of the occipital condyles and the oval cup-shaped superior facets of the atlas (C1) in transverse plane. Such an arrangement allows flexion-extension and lateral bending but very little axial rotation. The motion across the atlanto-axial unit is controlled by two groups of joints. The joints of the first group are the corresponding facet joints located laterally on opposite side between C1 and C2. The inferior articular surfaces of the C1 are relatively flat and the opposite superior articular surfaces of the C2 are round and slightly convex. The articulations of the second group include two parts, one between the odontoid process and the anterior arch of the C1, another between the odontoid process and

the transverse ligament. This arrangement allows a large amount of axial rotation, accounting for half of the axial rotation of the neck,(79) some flexion-extension and very little lateral bending across C1-C2. The structure of C0-C1-C2 is unique in several ways. It lacks intervertebral discs; the facet joints are orientated in horizontal plane with loose facet joint capsules and relative flat contours. These make the complex lacking bony constraint by the bone structure itself, thus allowing more extensive multidirectional mobility than any other level of the cervical spine. The odontoid of the C2 is the keystone as well as the pivot in this complex structure, contributing significant structural stability to the C0-C1-C2.(93)

Meanwhile, just as the bony articulations are specific to this region, so are the ligamentous structures. The C0-C1-C2 has surprising multidirectional stability, because of the restriction by strong intricate interconnecting array of ligaments from the occipital bone (C0) to C2.(36, 79, 91, 93) The odontoid, being strongly held pincer-like between *the transverse ligament* (an extremely strong ligamentous band extending between tubercles on the anteromedial sides of the paired C1 lateral masses and passing posteriorly around the odontoid) and *the C1 anterior arch*, prevents translational movement of C1 on C2. The odontoid is providing the primary ligamentous attachment points to the C0 and C1. There are *the apical ligament, the paired alar ligaments* and *the paired accessory ligaments*

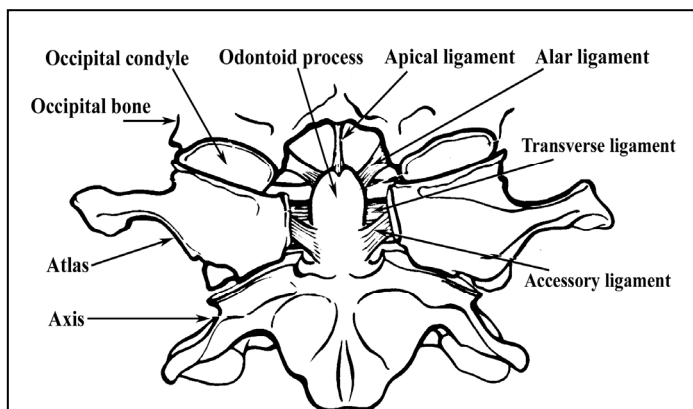


Figure 1 Coronal section of C0-C1-C2 with anterior arch of the atlas removed to illustrate the anatomical relationships and ligamentous attachments of the odontoid process.

Citing from the literature of Schatzker et al(93)

(fanning out from the superior, the superolateral and the lateral aspects of the odontoid to the anterior lip of the foramen magnum, inner aspects of the occipital condyles and the anteromedial aspect of the atlantal lateral masses nearby the transverse ligament attachment respectively). (Figure 1) There still have *the capsules of the facet*

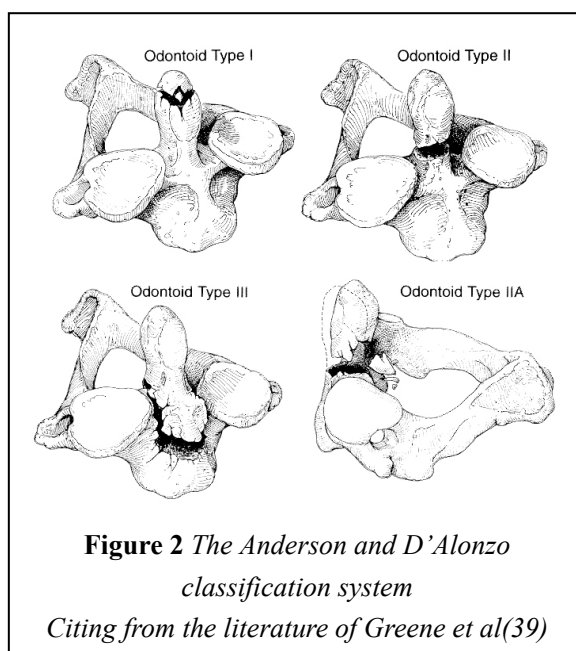
joints, the anterior longitudinal ligament, the tectorial membrane (the continuation of the posterior longitudinal ligament, attaching to the anterior margin of the foramen magnum) and *the interspinous ligaments* in this area, but they are too weak to withstand physiological loads by themselves.(69) Thus with a fracture below the transverse ligament, stability is lost and subluxation or dislocation may occur.(36, 91, 93)

1.3 Classification of Odontoid Fractures

The Anderson and D'Alonzo classification system,(5) (Figure 2) the classic and most widely applied categorization of odontoid fractures by simple anatomic type, clinical outcome prediction and the ability to direct appropriate management decisions, was described initially in 1974. The system classifies odontoid fracture into three types on the basis of location of the fracture plane.

Type I fracture is an oblique-to-transverse avulsion fracture near the tip of the odontoid above the transverse ligament. They are clinically rare, accounting for only 1–5% of odontoid fractures.(39, 94)

Type II fracture has a fracture plane crossing the base or waist of the odontoid process at the junction with the C2 body and is inherently unstable. It is the most common type of odontoid fracture and accounts for about 60% in the general population and more than 90%



of odontoid process fractures in the elderly.(40, 44, 60, 71)

Type III fracture line go from the odontoid extending into the C2 body. Type III fractures account for 15% to 40% of all odontoid fractures.(39, 40, 44)

Type IIA odontoid fracture, about 5% of all type II fractures, is a type II fracture with marked comminution at the base of the odontoid process. Hadley et al. further identified a type IIA subtype to this

classification scheme in 1988.(41) The type IIA fracture was associated with too severe instability to obtain and maintain fracture reduction and realignment.(41)

1.4 Pathology and Pathophysiology of Odontoid Fractures

Type I odontoid fractures are stable with the intact transverse ligament remaining attached to the odontoid process.(39, 94) This infrequent fracture is generally thought to occur by avulsion of the apical and/or the alar ligaments from the tip of the odontoid process and to be relatively stable. It does not seem to be of great clinical significance, although there has been reported that this avulsion fracture type can be in association with severe C0-C1-C2 instability and result in death, particularly if bilateral avulsion of the alar ligaments or a contralateral occipital condyle fracture is present.(63, 94) Type III fractures, with a predominance of cancellous bone and larger surface area of the fracture plane than that of type II fractures, are relatively stable unless severely displaced. Nonunion rarely occurs in this fracture type.(37)

Type II fractures have a weaker tendency for uniting spontaneously.(13) The causes of higher nonunion rates for type II fracture are multifactorial. Most of the odontoid process is intraarticular and type II fractures occur at the junction of the odontoid process and the C2 vertebral body in the synovial environment where the fracture fragments are lack of periosteum. These mean healing of the fracture can occur only by endosteal new bone formation which requires close contact between the surfaces of the fracture and adequate immobilization.(59) Intact apical and alar ligaments may demonstrate contraction over time, this can cause increased fracture separation by pulling the superior fragment upward and contribute to the nonunion of type II fracture after delayed treatment.(37, 59, 93, 98) Due to motion at the fracture site, it is very difficult to obtain adequate stabilization. (6, 37, 58, 62) Relatively small fracture surfaces with the deficiency of both the bone mass and the number of trabeculae(4, 47) make the type II fracture the most common type to develop nonunion.(98) The degree of fracture displacement also limits the effectiveness of immobilization. It was reported that nonunion with conservative treatment occurred in 20%-30% of type II odontoid fractures, but occurred in 67%-86% of those with dens

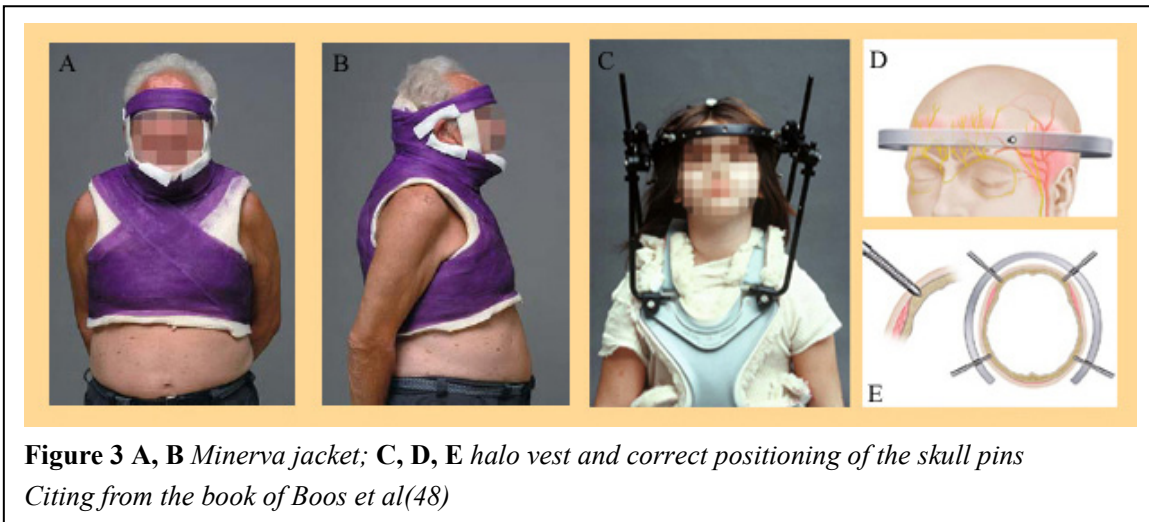displacement of 6 mm or greater regardless of age or direction of dislocation(13, 39, 40, 56), though advanced age(20, 37, 80) is also considered to cause nonunion. The disruption of the blood supply to the odontoid process, once believed to be a putative factor in the development of nonunion, is doubtful since the blood supply to the odontoid is not totally disrupted in acute fractures and nonunion.(37) No histological evidence of avascular necrosis but the interposition of the transverse ligament within the fracture gap was confirmed in ununited odontoid fractures.(16, 69)

The evil reputation held by odontoid fractures is due to the grave risk of spinal cord injury (SCI) which occurs with displacement of the C1 relative to the C2. The incidence of SCI of the patients with odontoid fracture has been reported to be low, ranging from 7.5% to 10%.(24, 39, 40, 42, 46, 80, 82) In fact, the C0-C1-C2 is one of the most common sites of dislocation in fatal cervical spinal injuries.(1, 17) Many studies have revealed that a significant proportion of deaths at the scene of traffic accidents, due to high level quadriplegia and respiratory arrest, are associated with axis fractures.(11, 42, 52) The fracture displacement and spinal canal size are identified as factors associated with risk of neurological injury.(23, 89) Though the overall mortality rate in survivors with SCI is high, many survivors with incomplete SCI can regain neurological function and have an independent daily living.(24, 37, 81, 95) It was shown that inadequate treatment of odontoid fractures can result in delayed neurological deterioration and myelopathy because of the repetitive trauma to the spinal cord secondary to instability(5, 16, 46, 88) or the compression of a hypertrophic nonunion(69), which can result in permanent and irreversible structural changes in the spinal cord.

1.5 Treatment Options for Odontoid Fractures

Achieving stability and bone union after odontoid fracture is critical for maintaining its keystone function and for preventing the potentially fatal acute instability at the C0-C1-C2 and the progressive myelopathy which may occur after chronic instability or nonunion.

In general, most of type I and III fractures, based on their relative stability, can be successfully treated with conservative management. Historically, conservative



management included closed reduction and external immobilization using soft collar, rigid cervical orthosis, Minerva jackets or halo vest.(18, 37, 44, 83, 95, 97) (Figure 3) Appropriate treatments for type I fractures consist of simple cervical collar immobilization and other external support which can result in successful fusion.(56) As noted previously, the exception to this rule is the type I fracture with severe C0-C1-C2 instability. Type III fractures are generally regarded as simple, healing is mostly uneventful if reduction can be maintained with conservative management for the relatively large cancellous fracture surface.(37) Immobilized with Halo vest or rigid cervical orthosis for 8 to 14 weeks has been reported to achieve highly successful union rates of 90% or more when closed reduction can be achieved.(37, 39, 40, 44, 56) If the C0-C1-C2 is severe instability and/or can not be immobilized adequately by conservative managements in type I or type III fractures, a posterior fusion is generally performed.(13, 39, 89) Otherwise, when the fracture plane is closer to the neck of the odontoid (high and shallow based), the type III fracture may act like a type II fracture, that is, with similar instability and an increased probability of nonunion.(13) In this situation, the “shallow” type III odontoid fractures are treated by the same methods as for type II fracture.(2, 27, 30)

Type II odontoid fractures are less stable, and associated with lower union rates than type I and III fractures.(13) The treatment algorithms for type II fractures are different from that for type I and type III. Halo vest has been confirmed to be the most reliable device for stabilization of the upper cervical spine.(87) But a high incidence of malunion and pseudoarthrosis with a mean nonunion rate of approximately 25% was reported using the Halo vest for immobilization of type II fractures.(5, 13, 20, 31, 37, 83, 93, 95) In fact,

the type II fractures are very difficult to be rigidly controlled externally.(37, 58, 62) Some scholars fluoroscopically observed odontoid fragment movement from 8 mm of anterior displacement to 8 mm of posterior displacement with each respiratory cycle in a patient in halo immobilization.(6) Other complications included stiffness of the neck, pin track infection, loosening of the pins, penetration of the skull, secondary displacement, cervical myelopathy, respiratory arrest and pressure sores.(25, 51, 95, 97) Evidence indicated that the more rigid the external immobilization, the stiffer the cervical spine would be.(25) It was reported that the Halo vest and other external fixation devices were poorly tolerated by the elderly and the multiply injured patients.(27, 33, 84, 100)

In an effort to improve the regained stability and reduce the corresponding complications, many surgeons have recommended primary surgical stabilization using atlanto-axial arthrodesis for type II odontoid fracture. These techniques include posterior wiring techniques with bone graft,(10, 32) posterior transarticular screws,(53) posterior polyaxial screw and rod fixation,(45) etc. Primary atlanto-axial arthrodesis, as an indirect stabilization method addressing the question of instability, has demonstrated an excellent rate of success to regain stability, but disrupts normal spinal elements and results in significant limitation of head and neck rotation which contributes to more than 50% of the normal rotatory excursion of the head and neck and reduction of normal cervical flexion and extension by 10%.(6, 81) Such procedures routinely require autologous bone graft collection, which may be associated with complication rates approaching 20 to 30% in some series by itself.(29, 102) The most ideal goals of any treatments for odontoid fractures would be a healed fracture with restoration of the normal anatomy and function of the atlantoaxial articulation.

As a progressive osteosynthetic technique, direct anterior screw fixation being a truly direct operative fracture treatment method, reported by Nakanishi(73) and by Bohler(8) at the beginning of 1980s, has been used to internally stabilize the type II odontoid fractures with intact transverse ligament and to overcome the limitations associated with either conservative methods or primary atlanto-axial arthrodesis. This method provides immediate rigid stabilization and allows for early active cervical spine mobilization with a minimal postoperative external support. It minimizes the iatrogenic trauma not only by

taking less traumatic to the surrounding soft tissues but also by avoiding the often discomfiting bone autograft procedure. Direct anterior screw fixation allows the best anatomical and functional outcome.(2, 27) Many scholars have reported high rates of fracture union from 90% to 100% (2, 6, 24, 27, 30, 50, 54, 56, 67, 81, 98) and full range of motion was maintained in 38% to 83% of their patients at following up.(12, 50, 54, 66, 81) The anterior screw technique using cannulated screws, being widely adopted because of easy maintenance of screw path alignment without removal of the guide wire, is described in the following section.(2, 26, 27)

The most common postoperative hardware-related complication is screw pullout of the body of C2 prior to development of fusion.(6, 82) Other complications are screw backout(6) and posterior fracture redisplacements(2, 27, 82). Screw fracture can also occur in patients in whom fusion did not occur.(2, 6, 27)

1.6 Indications and Contraindications for Anterior Screw Fixation

The acknowledged indications and contraindications for anterior screw fixation are listed beneath: (98)

1.6.1 Indications

- Age > 7 years
- Acute type II and “shallow” type III odontoid fractures with intact transverse ligament

1.6.2 Contraindications

- disruption of the transverse ligament
- odontoid fracture associated with comminution of one or both atlantoaxial joints
- unstable type III odontoid fracture
- Odontoid fracture associated with unstable Jefferson fracture
- Atypical type II odontoid fracture (comminuted or with an oblique fracture line in the frontal plane)
- Irreducible odontoid fracture/dislocation
- presence of marked thoracic kyphosis associated with limited cervical spine extension
- presence of severe spondylosis with spinal canal narrowing
- Pathological odontoid fracture

1.7 Anterior Screw Fixation Technique

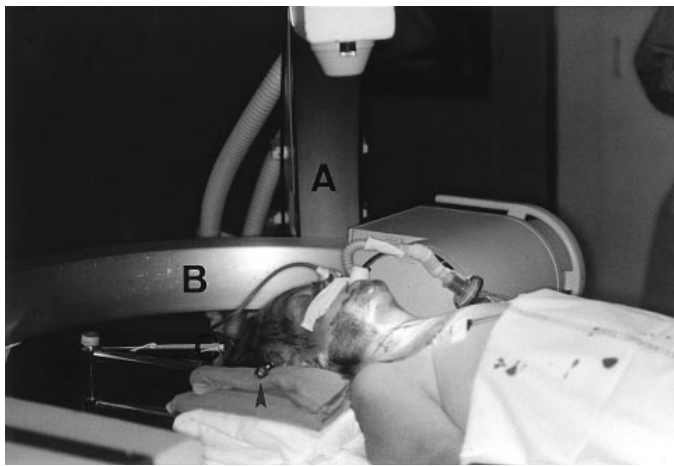


Figure 4, Patient's head extended and secured by skull tongs (arrow) with A-P (A) and lateral (B) fluoroscopic guidance.

Citing from the literature of Morandi et al(68)

After closed anatomic reduction of the odontoid fracture (in case of displacement) under biplanar (anteroposterior and lateral) fluoroscopic guidance, the patient is placed in supine position with the head extended and secured by external fixation. (Figure 4) A routine anteromedial approach from the level of C5/C6 disc, for the steep

angle required for screw placement, is performed with blunt dissection to the screw entry point at the inferior end plate of C2 anteriorly. The guide wire for the screw is inserted under biplanar fluoroscopic control. Coronally, the screw trajectory should be along the midline (one-screw technique) or the paramedian axis that angles toward the midline (two-screw technique). Sagittal orientations reach the opposing apical cortical bone of the dens. The proper length of the screw can be directly measured because it is just the

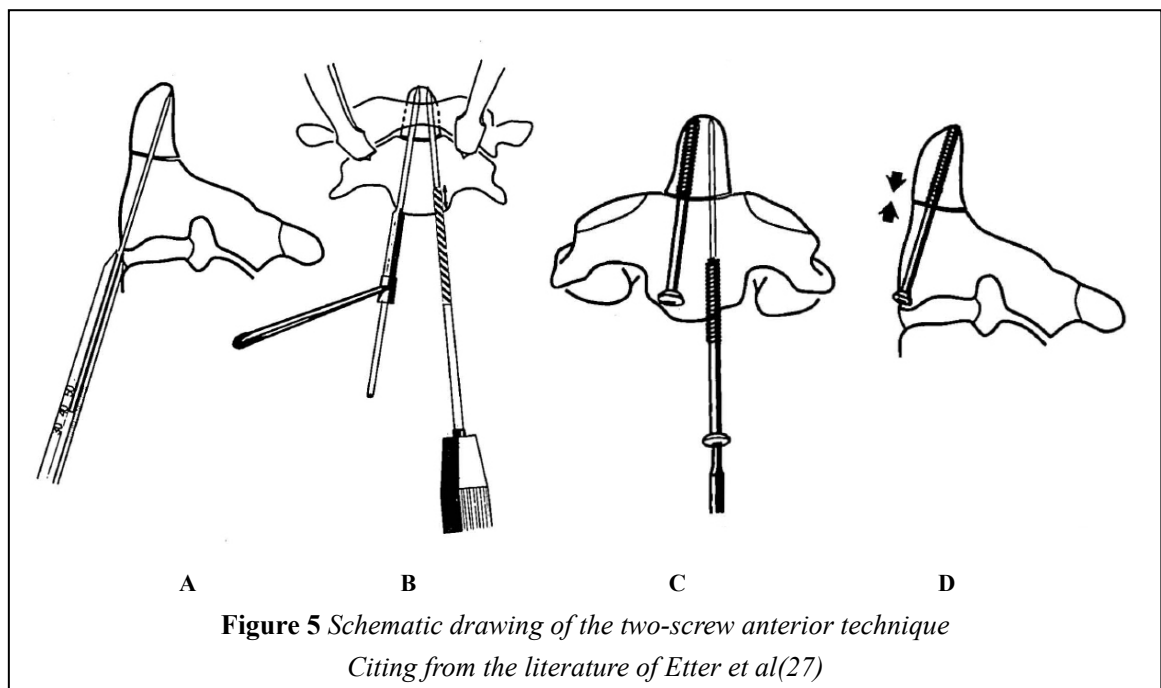


Figure 5 Schematic drawing of the two-screw anterior technique

Citing from the literature of Etter et al(27)

insertion depth of the guide wire. A suitable cannulated pilot drill bit is passed over the guide wire. (Figure 5 A, B) A cannulated, partially threaded, compressing screw with proper length is inserted along the guide wire from the anteroinferior edge of C2 vertebral body, across the fracture line, to the apex of the odontoid. The distal threaded part of the screw must enter the odontoid fragment entirely and engage the cortical tip of the odontoid, in order to maximize the compressing effect. Then the guide wire is taken out. (Figure 5 C, D)

1.8 Controversial Discussion about Anterior Screw Fixation

Despite the direct anterior screw fixation has been applied for type II odontoid fractures widely, there is still controversial discussion about the appropriate method for Type II odontoid fracture fixation: one- or two-screw technique.

There are many surgeons who prefer to use two-screw for the type II odontoid fracture.(2, 6, 9, 24, 27, 54, 81, 82, 86) A theoretical biomechanical advantage, two screws affording better stability for bending and rotation than one screw, especially providing rotational control of the fragment, exists for the using two-screw fixation technique as opposed to the one-screw technique. However, it is always a formidable challenge for every surgeon to insert two screws through odontoid process with relative small size and many vital anatomic structures nearby. Morphological studies suggested the diametrical dimensions of the odontoids in a significant percentage of patients would be insufficient to accommodate the passage of two screws with 3.5mm diameter or larger and only one screw could be successfully placed.(49, 74, 92)

Recently, some literature reported successfully using one-screw fixation for type II odontoid fracture.(12, 26, 30, 50, 61, 96, 98) Some clinical researches showed that there were no clinical advantage to using a two-screw construct and no significant difference in overall fusion rates between one- and two-screw fixation occurred.(7, 30, 55, 67) It has to be mentioned that the sample size of these clinical studies and other limitations of the study design make a definitive conclusion about one- or two-screw fixation impossible. The one-screw fixation technique has its realistic benefits for both of the patients and

surgeons. Because it means not only simplifying operation process and shortening the time spent, but also obviously reducing the radiation dose absorbed by both surgeon and patient. One-screw technique is easier to be finished and decreases the risks faced by both patients and surgeons. Using one screw occupies less surface area of the fracture than two screws, thus augments the actual bone-bone contact of the fracture site.

But no one can deny the hypothesis that the rotatory forces, created by alar ligaments and accessory ligaments during head rotation,(21, 22, 67, 99) would be better resisted by two screws than by one, especially in a fictional model of a straight transverse type II odontoid fracture. The insertion of one-screw may cause rotation of the fracture fragment during and after the process that screw is inserted through the fracture. Another adverse hypothesis for one-screw technique is that one screw may not be as strong as two screws in bending or shear load because the odontoid must resist bending and shear forces in both the sagittal and coronal planes.(70) Some literature have described, that screw loosening and screw fracture happened in some cases using one-screw fixation.(2, 6, 8, 27)

There are strong advocates of both one- and two-screw fixation of type II odontoid fracture based on small clinical studies. Both of the methods have theoretic contrary merits of their own. Clinical therapeutic decisions should be based on the outcomes of not only clinical observations but also basic theoretical research. There are many factors, including osteogenesis, contact of the fracture surfaces, compression at the fracture site, stable fixation of the fragments, that affect the possibility of bony union.(69) Beyond all doubt, the stability produced by anterior screw fixation for odontoid fracture is one of the most important biomechanical characteristics that directly affect bone healing. Furthermore, it also affects the design of therapeutic plan and the prognosis after odontoid fracture.

1.9 Objectives of current study

The aim of this study is the comparison of the stability between one- and two-screw fixation methods for odontoid fractures in an in-vitro biomechanical cadaver trial.

II. Materials and Methods

2.1 Materials

2.1.1 Specimens

5 Fresh C0-C1-C2 and 9 fresh C2 were harvested from human cadavers at the anatomic department of Luebeck University. The donators had given their consent to use their cadavers for postmortem medical scientific trials at life time. (Details see Table 1)

Table 1. Gender, Age and Bone Mineral Density (BMD) of Specimens

Group A				Group B			
No.	Gender	Age (years)	BMD (mg/cm ²)	No.	Gender	Age (years)	BMD (mg/cm ²)
1600	Female	98	52.10	1599	Female	84	107.40
1603	Male	69	593.90	1601	Male	81	631.00
1617	Male	66	688.20	1605	Male	81	726.70
1623	Female	60	535.60	1614	Female	86	167.70
1644	Male	78	447.50	1620	Male	69	240.30
1647	Male	68	782.50	1631	Male	76	312.00
1648	Female	87	241.10	1649	Female	88	221.10
mean ±SD		75.14±13.37	477.27 ±255.63	mean ±SD		80.71±6.47	343.74 ±239.02
The mean of the whole group:				age 77.93±10.50 BMD 410.51±247.65			

2.1.2 Fracture compression screw (FCS)



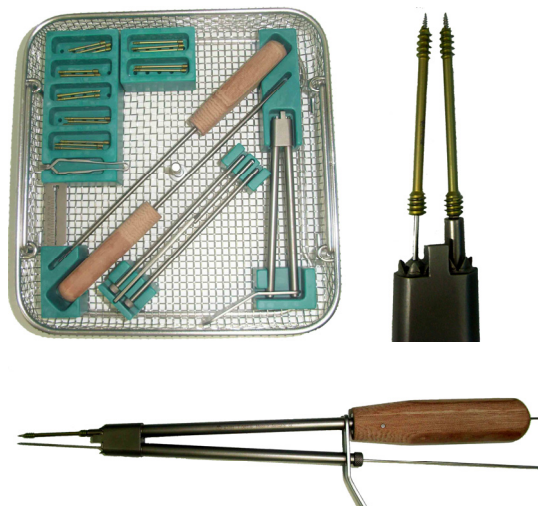Königsee, Königsee Implantate und Instrumente, Aschau, Germany

Diameter 4.0 mm / 3.0 mm, self-tapping, self-drilling, titanium

Structure	Head		Shank		Hexagon socket	Cannulation
	Screw	Core	Screw	core		
Diameter (mm)	4.0	2.9	3.0	2.0	2.0	1.3
Length (mm)	3.5		6.0			
Pitch (mm)	1.0		1.25			

2.1.3 Instrument Kit for Anterior Screw Fixation of Odontoid Fracture

Königsee, Königsee Implantate und Instrumente, Aschau, Germany



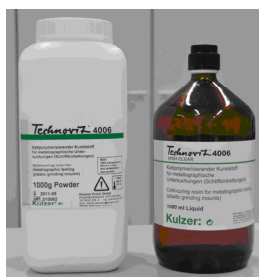Tissue protecting drill apparatus	outer	1
	inner	2
Screw-driver (cannulated, hexagonal)		1
Cannulated pilot drill bit (cutter short)		1
Screw forceps		1
Gauge for fracture compressing screw		1
Guide wire (1.2mm) and FCS		many

The tissue protecting drill apparatus has two guide lines and each is a double sleeve structure. Under its guiding, the distance between the two screw entry points is 8 mm and the angle of the two screws is 10°.

2.1.4 Computer Tomography Machine

Toshiba 32-slice CT (Tokyo, Japan) intalled at the Radiology department of the Berufsgenossenschaftlichen Unfallkrankenhauses Hamburg.

2.1.5 Embedding Resin



Used for embedding the axis of the specimens
polymethylmetacrylate
Technovit 4006
Heraeus Kulzer GmbH,
Wehrheim, Germany

2.1.6 Biomechanical Testing Generic Block



The material behaves as light cortical bone and is used for fixing the occipital of the specimens.
Synbone PR0020 with 0.19g/cm³ density.
Synbone AG,
Malans, Switzerland

2.1.7 Universal mechanical Testing Machine (UTM)



Zwick UTM 145670

Control software: Zwick Software 1005, V 3.0

Zwick GmbH & Co. KG

Ulm, Germany

2.1.8 Linear Variable Incremental-optical Displacement Transducer (LDT)



Megatron MS30-1-LD-2

Megatron Elektronik AG & Co. Industrietechnik

Putzbrunn, Germany

Optical resolution 2µm

2.1.9 Optoelectronic Incremental Rotary Encoder



Megatron MOB 2500 5 BZ N

Megatron Elektronik AG & Co. Industrietechnik

Putzbrunn, Germany

Optical resolution 2500/360°

2.1.10 Torque Sensor



Burster, Model 8627-5010

Burster Praezisionsmesstechnik GmbH & Co. KG

Gernsbach, Germany

Measurement range $\pm 10\text{Nm}$

2.1.11 Self-designed and Custom-fit Devices

2.1.11.1 Rotational Testing Device (RTD)

The *gear-driven* RTD has two main parts, the rotational part and the holding part. The rotational part is mainly composed with a gearwheel, a torque sensor and a circular metal





plate for fixation of the specimen. They are fixed together in the same pivot axis and can rotate freely. The holding part is a global mounted framework which is set up in the vertical plane. The biggest framework was fixed on a directive slide track which made the frame move freely in fore-and-aft direction. The other two frameworks can be freely turned around the horizontal and vertical central axis of the biggest framework respectively. The structures make the frame move freely except rotate in the pivot axis of the rotational part. The pivot axis of the rotational part is perpendicular to the plane of the biggest square framework at the central point.



2.1.11.2 Spring Clamp

The special designed spring clamp has two springs, two opposing parts and one control handle. The two opposing parts are self-guided to keep sufficient

interface with different figures of odontoids. The two springs make the two opposing parts fasten and the control handle can adjust the strength to clamp the odontoid stable enough during testing.

2.1.12 Application Software

1. SPSS statistics 17.0, SPSS Inc. (Chicago, USA)
2. DIAdem 11.0, National Instruments Ireland Resources Limited. (Austin, USA)

2.2 Subjects and Methods

The overall design of the study is composed by two parts, the preliminary experiments and the main experiments, for investigating the study objective. The displacement data in relation to the load were collected continuously over the whole study with a frequency of 100Hz by the data collecting computer.

2.2.1 Preliminary Experiments

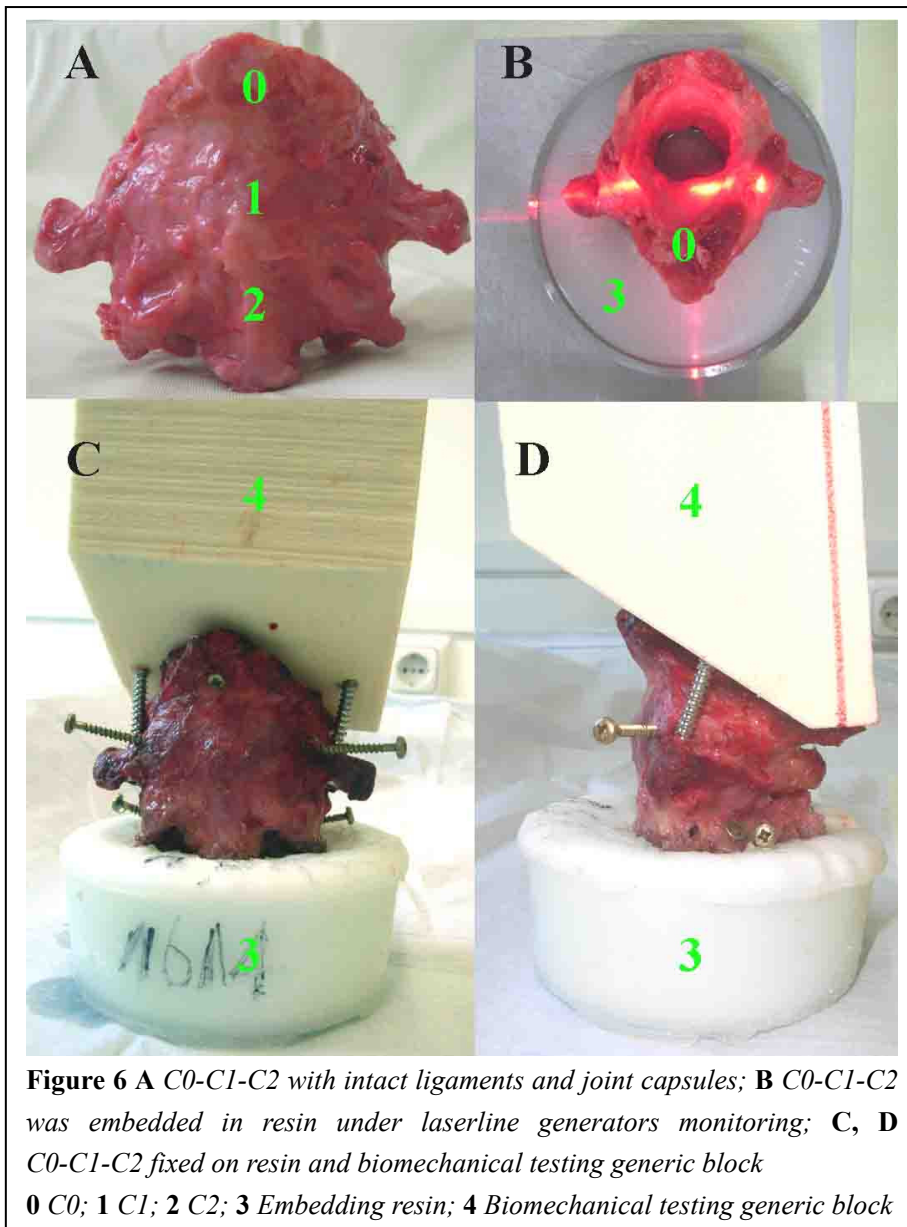
2.2.1.1 Objective

To investigate how much torsional load is transmitted to the odontoid by ligaments in normal physiologic condition.

2.2.1.2 Specimen Preparation

5 fresh C0-C1-C2 (2 male, 3 female) with an average age of 76 years (range 60 to 86 years) were carefully preserved the integrity of all the ligaments and joint capsules and were resected all the muscles and the other soft tissues. (Figure 6 A)

The C2 was embedded in an interior columniform metal container by resin to provide a firm base of support. During the resin was curing, the pivot axis of the odontoid was kept in vertical orientation to the base of the container at the central point with monitoring by two laserline generators. (Figure 6 B) The undersurface of the C2, including the inferior articular process of C2, was fully contacted with the resin. The resin did not overrun the superior articular surface and vertebral arch in order to make the C2 being able to be freely



taken out and re-embedded in the resin during study. After the resin was cured, the C2 was reinforced by two screws from the inferior articular process and the spinous process to resin.

C0 and C1 of the specimens were fixed on a biomechanical testing generic block by screws through the bone of C0 and

bilateral transverse foramens of C2 respectively. On both lateral sides of C1 and C2, four screws were symmetrically fixed on the vertebra along the coronal plane as the markers for measuring rotational motion. (Figure 6 C, D)

Then the specimens were sealed in double plastic bags and were kept frozen at -20°C. On the testing day, they were fully thawed at room temperature and were kept moist by spraying the specimens with 0.9% physiological saline solution during testing.

2.2.1.3 Testing Apparatus Setting

The RTD was stably fixed on the testing table of UTM and was assembled with the UTM by connecting the gearwheel to the load bar. Thus, when the load bar of the UTM




Figure 7 A, B Testing Apparatus Setting of Preliminary Experiments

1 Loading bar; **2** Gearwheel of the RTD; **3** Torque sensor; **4** Frame of the RTD; **5** Biomechanical testing generic block; **6** Circular metal container; **7** Rotary encoder; **8** Data collecting computer; **9** Control computer of the UTM

was moved up and down, the RTD could change the linear load to left and right torsional load. The load bar of the UTM could change the moving direction automatically as soon as the maximal load was reached.

On the left and right rims of the smallest framework, there were three pairs of screws which can be adjusted vis-à-vis to fix the testing block with the specimens onto the frame. A circular metal container, mounting the embedding resin, was fixed on the plate of the RTD in the same pivot axis. Then the resin side of the specimen was bolted firmly in the circular metal container. Under this combination, the C0-C1-C2 can be fixed on the RTD in physiological neutral position. The C2 was rigidly fixed but can rotate with the rotational part of RTD together. Both the odontoid and the RTD are in the same pivot axis. The C0 and C1 can move freely except rotation in the pivot axis of the odontoid.

After the prepared C0-C1-C2 were neutrally fixed on the RTD, the four screw markers on C1 and C2 were kept on a horizontal plane and were connected to the rotary encoders by threads symmetrically. Four 100g plumbs were tied on the end of the four threads respectively. The direction of the threads was retained at plumb line by pulleys. The torque sensor and the rotary encoders were connected with the data collecting computer. The relative angular displacement between C1 and C2 can be automatically calculated and recorded by the data collecting computer. (Figure 7 A, B)

2.2.1.4 Study Procedure

A continuous clockwise-counterclockwise axial rotation with 5°/s rotational speed and

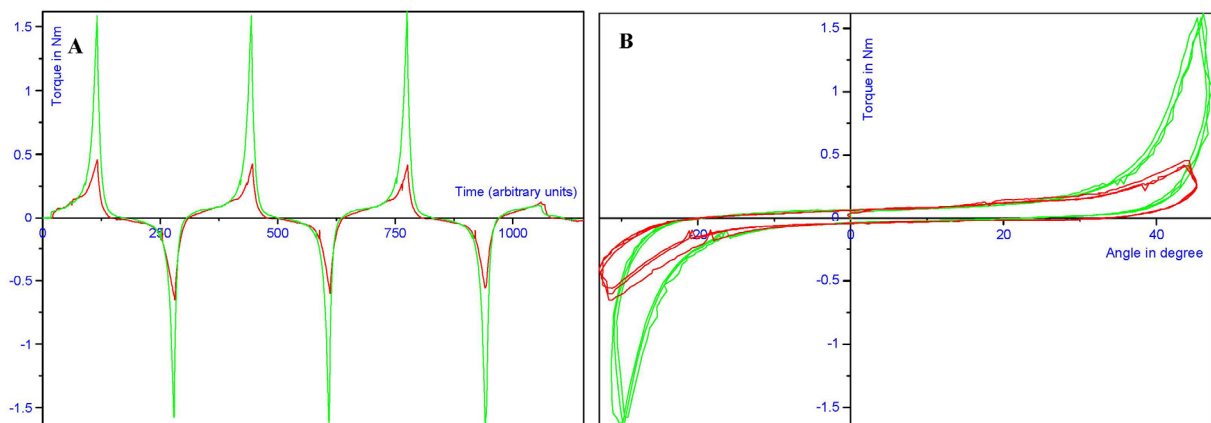


Figure 8 **A** torque-time curve; **B** torque-angular displacement curve. (Green curve: intact specimen; Red curve: after cutting off ligaments)

up to $\pm 1.5\text{Nm}$ pure axial torque, namely, one test cycle, was applied to the RTD for simulating the left and right rotation between C1 and C2 normality. Three continuous test cycles are defined as one test series. Each of the specimens was tested in three series with 60s interval between two test series. Then, the torque-time curve and the torque-angular displacement curve can be achieved from the data collecting computer. The data can be read directly from the curves of the data collecting computer. (Figure 8 A, B)

In order to minimize the effect of viscoelastic responses, the first and second test cycle of each test series were used for preconditioning. On the third test cycle of the three test series, the clockwise-counterclockwise rotational angles under $\pm 1.5\text{Nm}$ torque were recorded respectively. The average unidirectional rotational angle was the unidirectional range of motion (ROM), defined as the angular deformation at maximum load, in normal physiologic conditions and was used in the next step.

Then all the ligaments (facet joint capsules, anterior longitudinal ligament and tectorial membrane between C1 and C2, etc) which do not attach to the odontoid were cut off or transected and the ligaments (alar ligaments, accessory ligaments and transverse ligament, etc) which attach to or contact with the odontoid were preserved. In order to facilitate the operation, the posterior arch of C1 was resected. (Figure 9 A, B, C, D)

Next, the specimen was fixed on the RTD again and rotated to the recorded left and right average ROM with $5^\circ/\text{s}$ rotational speed. Three test series, each including three continuous test cycles, were repeated with 60s interval. On the third test cycle of the three test series,

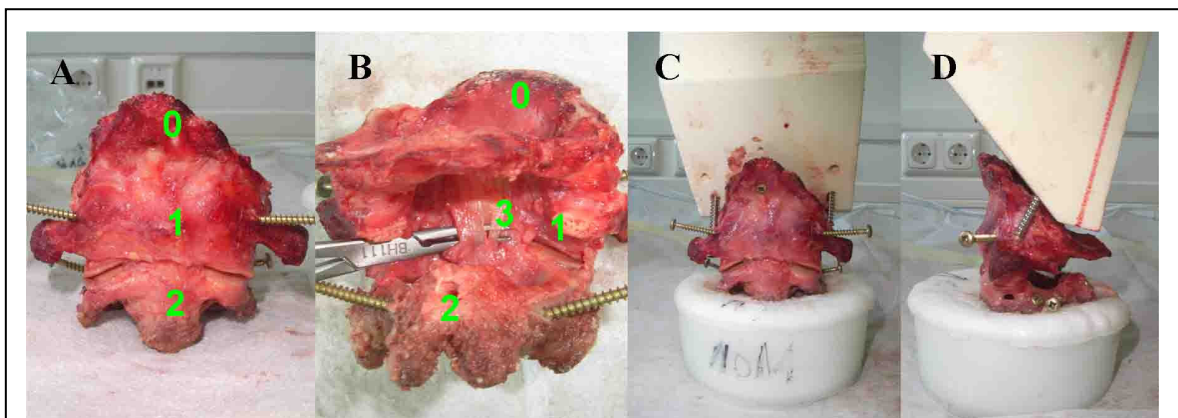


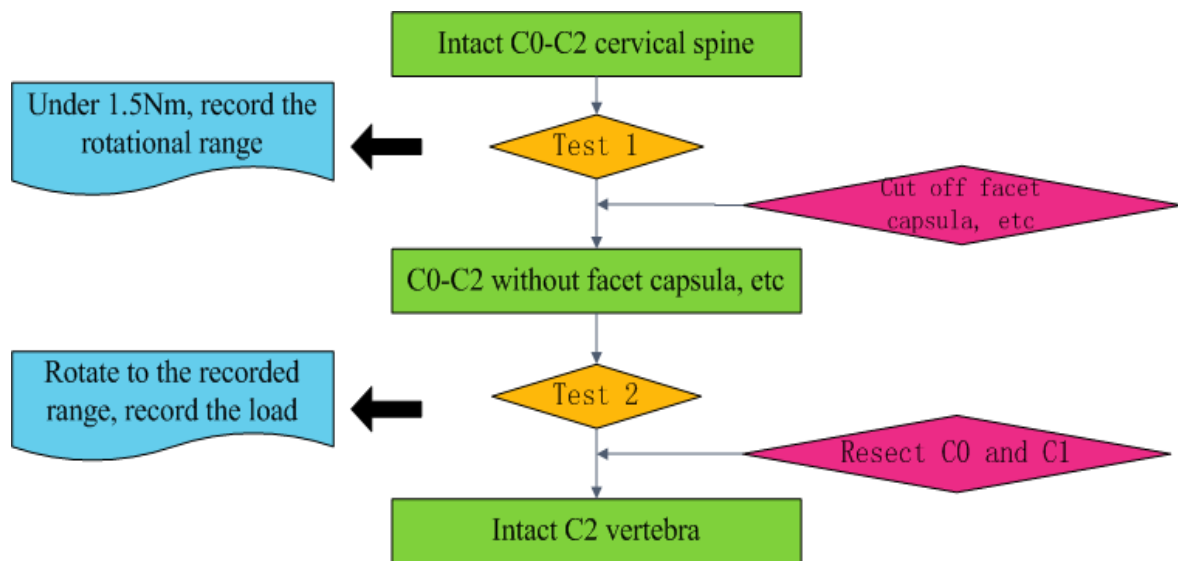
Figure 9 A, B, C, D cut off facet capsules and posterior arch; transect anterior longitudinal ligament and tectorial membrane.

0 C0; **1** C1 without posterior arch; **2** C2; **3** tectorial membrane

the maximum left and right torque was recorded. The average maximum torque in left and right rotation was the torsional loads that were transmitted to the odontoid by ligaments in normal physiologic conditions.

At last, the C0 and C1 were resected and the C2 was prepared for the main experiments of the study.

2.2.1.5 Study Flow Chart of Preliminary Experiments



2.2.2 Main Experiments

2.2.2.1 Objective

To investigate the stability of type II odontoid fracture models after one- or two-screw fixation.

2.2.2.2 Specimen Preparation

14 fresh C2 specimens (8 male, 6 female) with an average age of 77.9 years (range 60 to 98 years) were dissected for all soft tissue and cartilage removal. Before embedding, plasticene was placed around the anterior, lateral and anteroinferior surface of the C2 vertebral body in order to prevent resin-bone and resin-screw head of FCS interaction from lending extra stability to the specimen. The pivot axis of the odontoid was kept

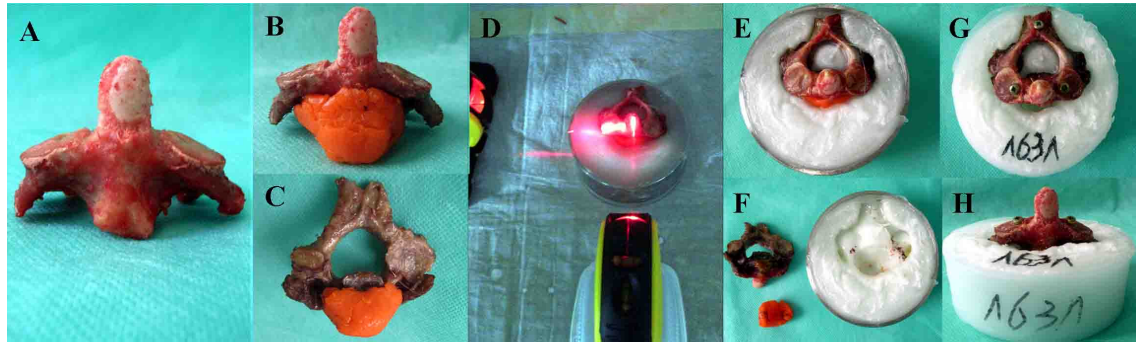


Figure 10 A C2; B, C Plasticene was placed around the anterior, lateral and anteroinferior surface of the C2 vertebral body; D, E C2 was embedded in resin under laserline generators monitoring; F Specimen was taken out and the plasticene was removed; G, H C2 was reinforced by three screws

perpendicular to the base of container at the central point under two laserline generators monitoring during embedding. After the resin was tightly cured, the plasticene was removed and the C2 was reinforced by three screws, two from the superior articular surface and one from the spinous process to the resin. By this way, the C2 achieved enough stabilization for testing without negative effects by the resin. The other details about embedding and preserving method were the same as the method used in Part I. (Figure 10)

2.2.2.3 Testing Apparatus Setting

2.2.2.3.1 Testing Shear Stiffness

The prepared C2 was bolted in the metal container which was mounted on the testing table of UTM. The base of the container was perpendicular to the horizontal plane. The load bar of UTM directly acted on the upper articular surface of the odontoid and the tip of the LDT's guided plunger touched the opposite articular surface. By rotating the resin in the metal container, the shear load can be applied from the anterior, posterior, left and right direction to the odontoid by the load rod. The data of shear load and linear displacement were transmitted from the LDT to the data collecting computer and the shear load-linear displacement curve can be achieved. (Figure 11)

2.2.2.3.2 Testing Torsional Stiffness

The spring clamp was fixed on the circular plate of the RTD in the same pivot axis with the RTD. Both the odontoid and the rotational part of RTD are in the same pivot axis after




Figure 11 A, B, C Apparatus Setting for Testing Shear Stiffness

1 Loading bar; 2 LDT; 3 C2; 4 Odontoid; 5 Control computer of the UTM; 6 Data collecting computer

the odontoid was stably held by the spring clamp. The circular metal container was mounted on the smallest framework via a metal plate. Then the resin of the prepared C2

was fixed in the container. When the load bar of the UTM was moved up and down, the left and right torsional loads were applied to the odontoid. The data of torque and angular displacement was transmitted from the sensors to the data collecting computer and the torque-angular displacement curve in left and right rotation was recorded. (Figure 12)




Figure 12 *Apparatus Setting for Testing Torsional Stiffness*

1 Loading bar; **2** Gearwheel of the RTD; **3** Torque sensor; **4** Frame of the RTD; **5** Circular metal container; **6** Spring Clamp; **7** Rotary encoder

2.2.2.4 The Definition of Study Parameters

1. Shear stiffness was calculated from the slope of the most linear portion of the shear load-linear displacement curve.
2. Torsional stiffness was calculated from the slope of the most linear portion of the torque-angular displacement curve.

2.2.2.5 Study Procedure

The 14 C2 specimens were assigned randomly to two groups. For this purpose, the

software on the web site www.randomizer.org was used. In **Group A**, only one FCS was used; In **Group B**, two FCS were used to fix the type II odontoid fracture models. The whole study procedure of part II was divided into two steps.

2.2.2.5.1 Step 1

Radiography (anteroposterior and lateral X-rays) were performed to rule out bony pathology of the C2. The bone mineral density (BMD) data of all the C2 specimens were obtained from computed tomography (CT) scan. Every C2 specimen was scanned three levels, namely, the vertebra of C2, the top and the base of the odontoid. The BMD of the C2 was defined as the mean BMD data of the three levels.

The embedded C2 specimens were mounted on the testing device of the UTM. The shear stiffness and the torsional stiffness were measured using a nondestructive low-load test. When testing shear stiffness, the maximum load was 40N and the load speed was 0.1mm/s; when testing torsional stiffness, the maximum torque was 0.75Nm and the rotational speed was 0.1degree/s. The shear load was applied from four directions, namely, from anterior to posterior, from posterior to anterior, from left to right and from right to left. The torsional load was applied in left rotation and right rotation. Then the stiffness of the intact odontoid in six directions, namely, shear stiffness loading from anterior (SA), shear stiffness of loading from posterior (SP), shear stiffness loading from left (SL) and shear stiffness loading from right (SR), torsional stiffness in left rotation (TL) and torsional stiffness in right rotation (TR) was calculated from the shear load-linear displacement curves and torque-angular displacement curves respectively.

2.2.2.5.2 Step 2

Guide wires were placed from the anteroinferior edge of C2 vertebral body to the apex of the odontoid. In *Group A*, one guide wire was inserted through the midline of the coronal plane. In *Group B*, two guide wires were inserted under the tissue protecting drill apparatus guiding. Thereby, the distance from the screw entry points to the midline was 4mm and the angle between the guide wire trajectories and the midline in coronal plane was 5° in *Group B*. The appropriate guide wire trajectory in sagittal plane of *Group A* and

Group B was the same and described above. The proper length of the FCS can be directly measured by the gauge over the guide wire. Then the guide wires were taken out.

An osteotomy was created at the junction of the dens and vertebra with a thin saw by hand to simulate a Type II odontoid fracture. Then the two fracture fragments were reduced anatomically and the guide wires were inserted again through the original trajectory. The two fracture fragments were tightly held with compression between the two fragments by a clamp.

The cannulated pilot drill bit was used to open the bony entry point for the FCS over the guide wires by hand and no tapping are required for the threads of the FCS. The FCS was introduced by hand over the guide wire and 1 or 2 threads over-penetration through the apex of the odontoid can eliminate one variable by ensuring that all screws engaged the same amount of bone. The tightening was stopped when the thread of the FCS head totally entered the vertebra. Then anteroposterior and lateral X-ray films were performed to prove satisfactory reduction and fixation. (Figure 13, 14, 15)

The specimens were mounted and tested in the same positions and orientations on the testing device of the UTM again. The stiffness in six directions was tested with the same parameter setup as in step 1.

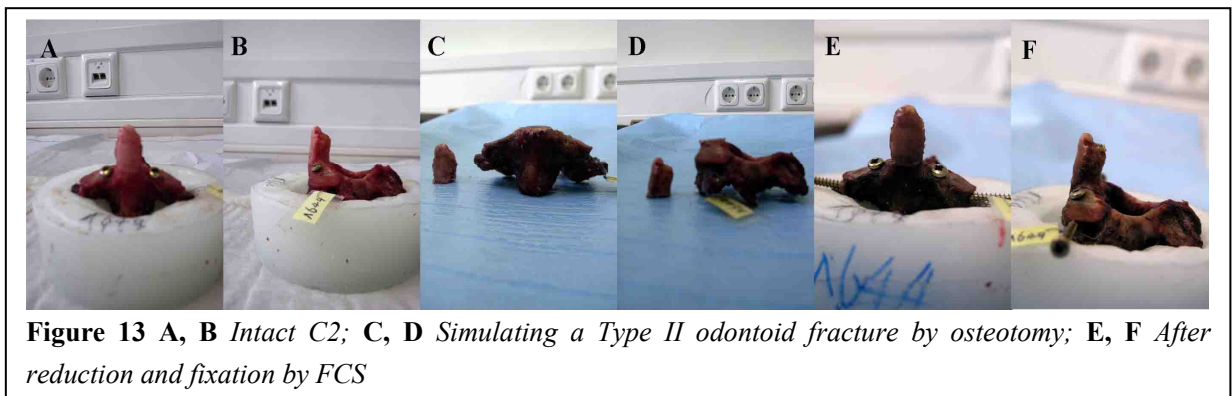


Figure 13 A, B Intact C2; C, D Simulating a Type II odontoid fracture by osteotomy; E, F After reduction and fixation by FCS

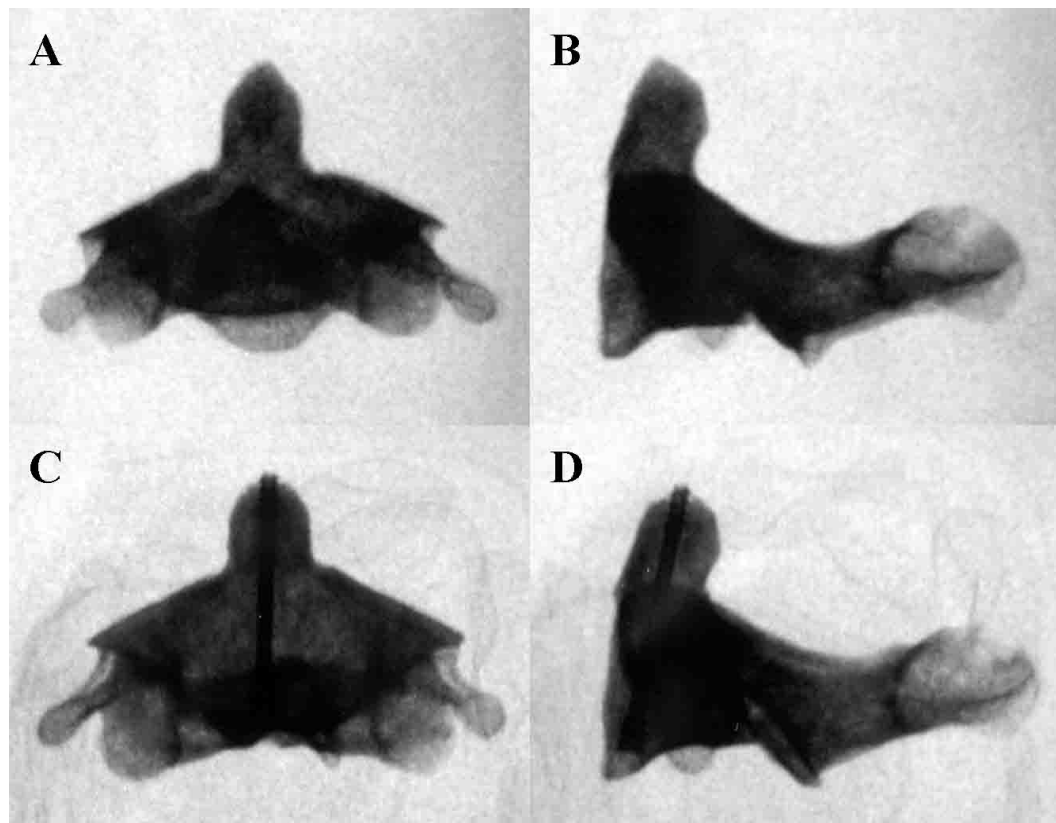


Figure 14 A, B *Intact C2*; C, D *One-FCS fixation after osteotomy*

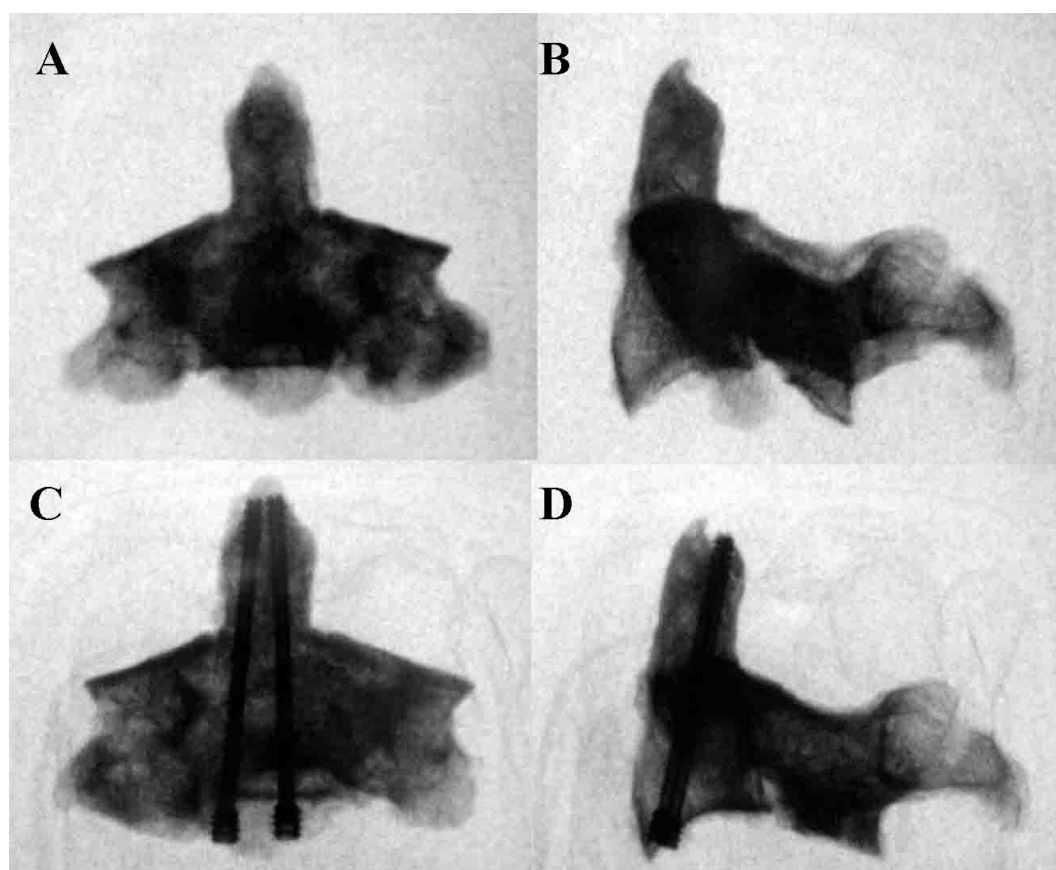
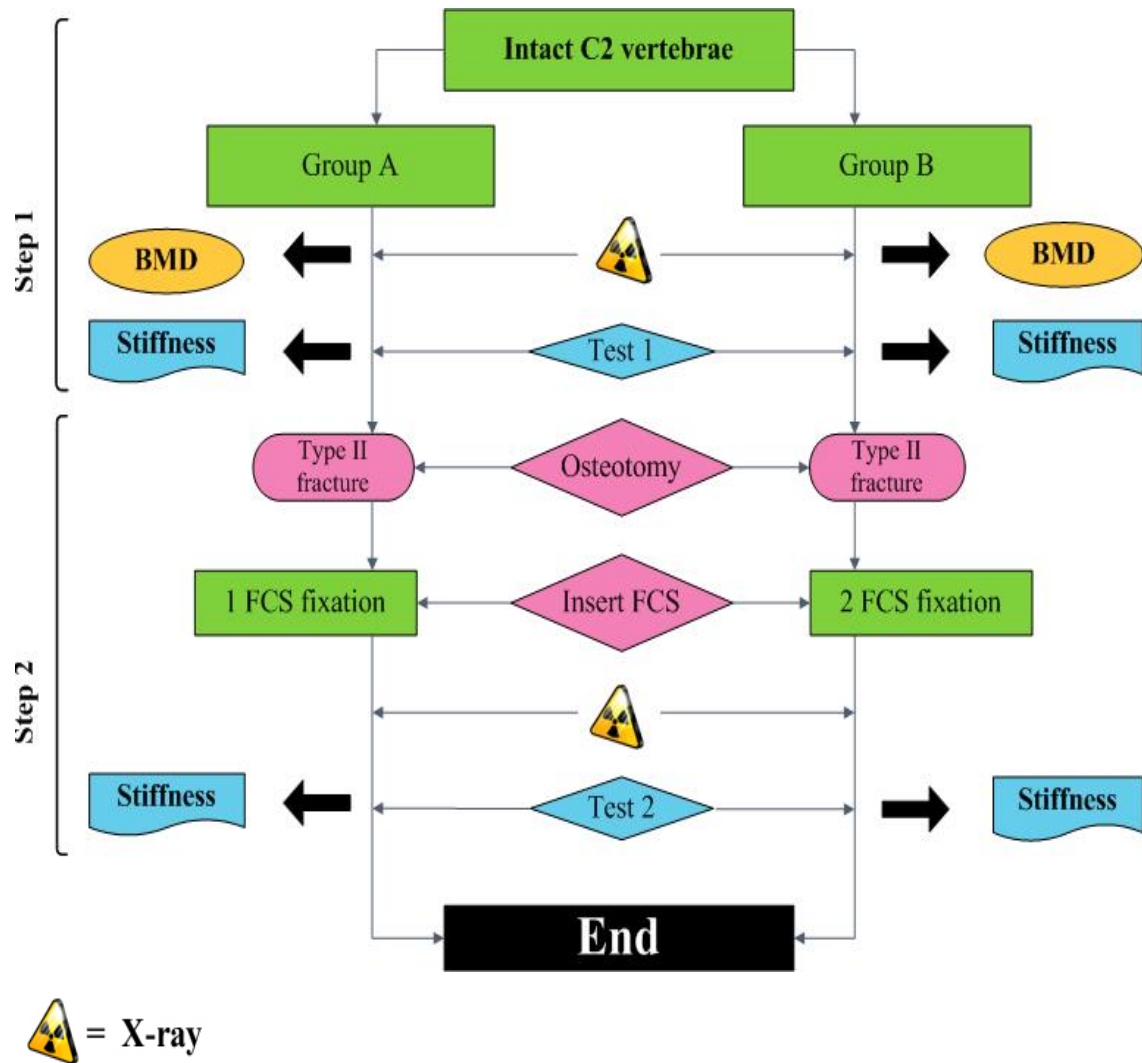


Figure 15 A, B *Intact C2*; C, D *Two-FCS fixation after osteotomy*

2.2.2.6 Study Flow Chart of Main Experiments



2.2.3 Data Processing and Statistical Analysis

2.2.3.1 Data Processing

Data collecting and processing was carried out with DIAdem 11.0. (Table 1-7) There were some irregularities in the data tables to be explained:

1. The vertebra of the No. 1600 was cut by the FCS during testing the shear stiffness, No. 1620 and No. 1649 specimens were broken by the spring clamp during testing the torsional stiffness after FCS fixation. The stiffness data that could not be tested were mentioned by “000” in the tables.
2. The shear stiffness of intact No. 1617 specimen loading from right was excluded for being statistically unconventional higher than the others.

2.2.3.2 Statistical Analysis

Data are expressed as mean \pm standard deviation (SD).

One sample *t* test was used to compare the mean torque load that is transmitted to the odontoid by ligaments with the 1.5Nm normal physiologic torque load that is applied to the C0-C1-C2.

Independent samples *t* test was used for statistical analysis of the differences between Group A and Group B.

Paired samples *t* test was used for statistical analysis of the differences between intact specimens and fractured specimens in a same group.

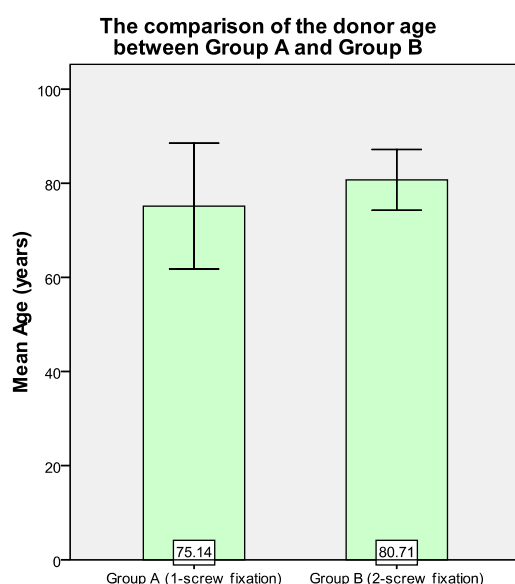
Bivariate correlations analysis (Pearson correlation coefficients) was used for the statistical analysis between the BMD and the stiffness.

Statistical significance was defined at $P < 0.05$. Calculations were carried out with SPSS statistics 17.0.

III. Results

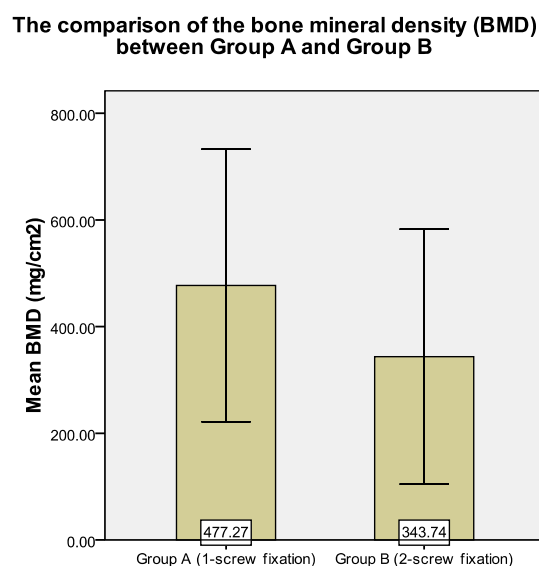
1. In the whole group, there were 14 specimens (8 males and 6 females) with the mean age 77.93 ± 10.50 years and the mean BMD of 410.51 ± 247.65 mg/cm².

The mean age for the Group A was 75.14 ± 13.37 years (range from 60 to 98 years) and for Group B was 80.71 ± 6.47 years (range from 69 to 88 years). Each of group has 4 males and 3 females. The BMD for the two groups was 477.27 ± 255.63 mg/cm² versus 343.74 ± 239.02 mg/cm². There was no statistically significant difference in mean donor age ($t=-0.992$, $P>0.05$) and BMD ($t=1.009$, $P>0.05$) between the two groups. (Details see Table 1; Graph 1, 2)



Graph 1

Error bars: ± 1 SD



Graph 2

Error bars: ± 1 SD

2. Based on the preliminary experiments, the mean unidirectional rotational ROM under 0.3Nm and 1.5Nm are $25.13 \pm 9.51^\circ$ and $34.49 \pm 10.18^\circ$ respectively, the corresponding mean torque load that is transmitted to the odontoid by ligaments is 0.17 ± 0.07 Nm and 0.53 ± 0.38 Nm. There was statistically significant difference ($t=-8.081$, $P<0.01$) between the mean torque load that is transmitted to the odontoid by ligaments and the 1.5Nm torque load that is applied to the C0-C2. After resection of the ligaments, the torque was reduced by 43.3% and 64.7% when the specimens were rotated to the recorded ROM of intact specimens under 0.3Nm and 1.5Nm respectively. (Details see

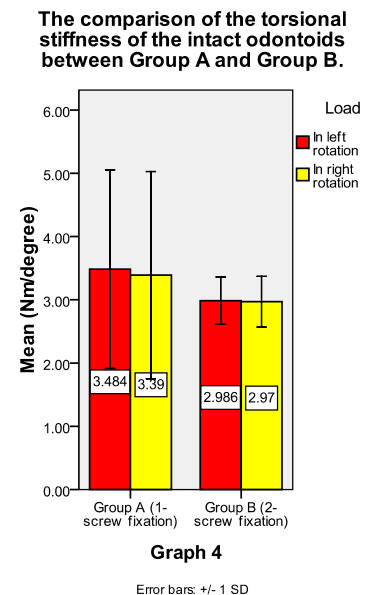
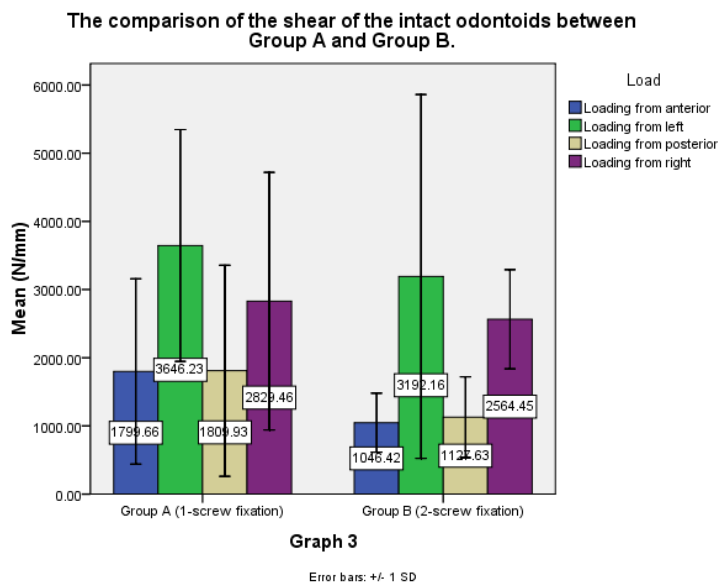
Table 2)

3. In the whole group, the BMD had statistical significant correlation with SA ($r=0.608$, $P<0.05$), SP ($r=0.672$, $P<0.05$), TL ($r=0.728$, $P<0.05$) and TR ($r=0.658$, $P<0.05$) of intact specimen. The statistical results did not show that the BMD had significant correlation with SL and SR of intact specimen.

According to the statistical results of Group A, there were not significant correlation between the BMD and all the six stiffness (SA, SL, SP, SR, TL and TR) after one-FCS fixation.

From the data of Group B, the BMD only had statistical significant correlation with SP ($r=0.817$, $P<0.05$) after two-FCS fixation. The statistical results did not suggest the BMD had significant correlation with SA, SL, SR, TL and TR after two-FCS fixation. (Details see Table 3)

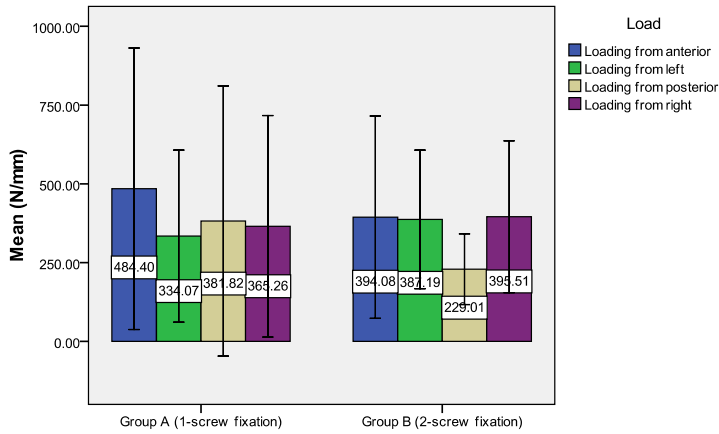
4. There was no statistically significant difference in mean stiffness of intact odontoid in six directions, namely, SA ($t=1.397$, $P>0.05$), SL ($t=0.380$, $P>0.05$), SP ($t=1.089$, $P>0.05$), SR ($t=0.345$, $P>0.05$), TL ($t=0.818$, $P>0.05$) and TR ($t=0.659$, $P>0.05$), between Group A and Group B. (Details see Table 4, 5; Graph 3,4)



5. There was no statistically significant difference in mean stiffness of odontoid after FCS fixation in six directions, namely, SA ($t=0.434$, $P>0.05$), SL ($t=-0.389$, $P>0.05$), SP ($t=0.913$, $P>0.05$), SR ($t=-0.183$, $P>0.05$), TL ($t=-2.081$, $P>0.05$) and TR

($t=-1.6$, $P>0.05$), between Group A and Group B. (Details see Table 6, 7; Graph 5, 6)

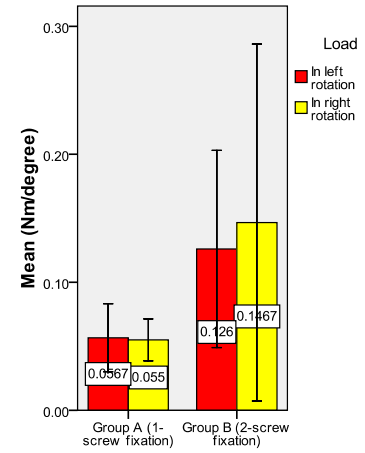
The comparison of the shear stiffness of the odontoids after FCS fixation between Group A and Group B.



Graph 5

Error bars: ± 1 SD

The comparison of the torsional stiffness of the odontoids after FCS fixation between Group A and Group B.

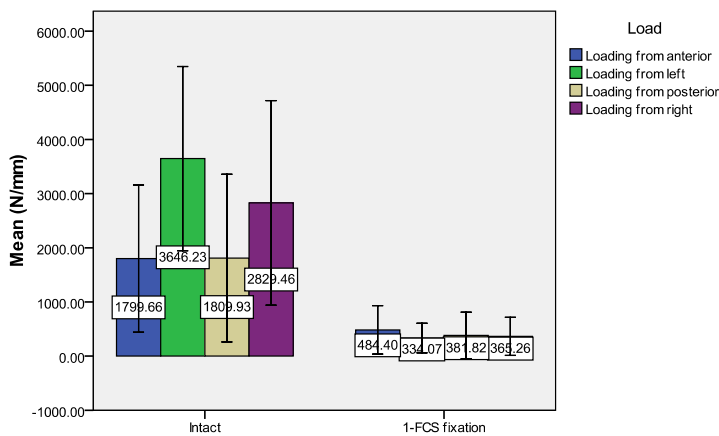


Graph 6

Error bars: ± 1 SD

6. In group A, there was a statistically significant difference in the mean stiffness of the odontoid between intact specimens and after 1 FCS fixation in six directions, namely, SA ($t=2.759$, $P<0.05$), SL ($t=5.085$, $P<0.05$), SP ($t=3.168$, $P<0.05$), SR ($t=3.030$, $P<0.05$), TL ($t=6.366$, $P<0.05$) and TR ($t=5.810$, $P<0.05$). (Graph 7, 8)

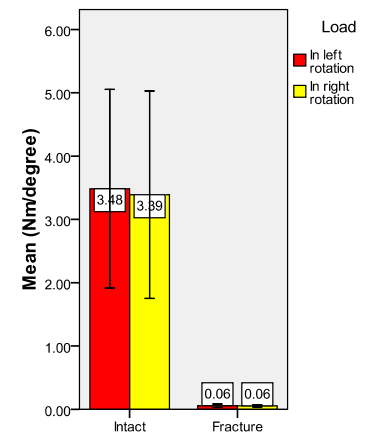
The comparison of the shear stiffness between the intact odontoid and after 1-FCS fixation in Group A



Graph 7

Error bars: ± 1 SD

The comparison of the torsional stiffness between the intact odontoid and after 1-FCS fixation in Group A



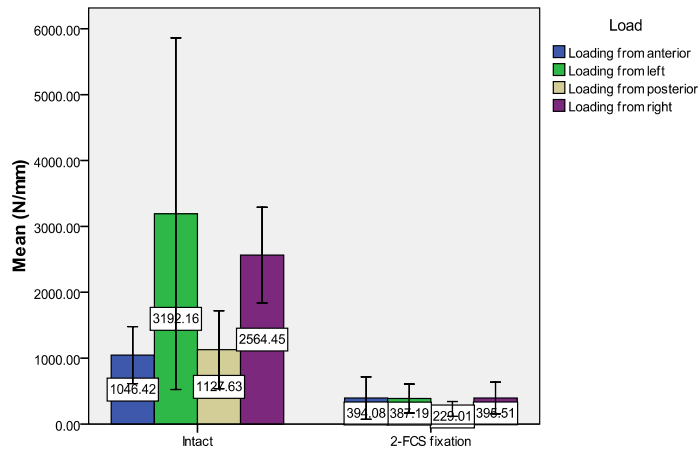
Graph 8

Error bars: ± 1 SD

7. In group B, there were statistically significant difference in mean stiffness of odontoid between intact specimens and after 2 FCS fixation in six directions, namely, SA ($t=3.931$, $P<0.05$), SL ($t=2.858$, $P<0.05$), SP ($t=4.600$, $P<0.05$), SR ($t=8.137$, $P<$

0.05), TL ($t=15.739$, $P<0.05$) and TR ($t=15.427$, $P<0.05$). (Graph 9, 10)

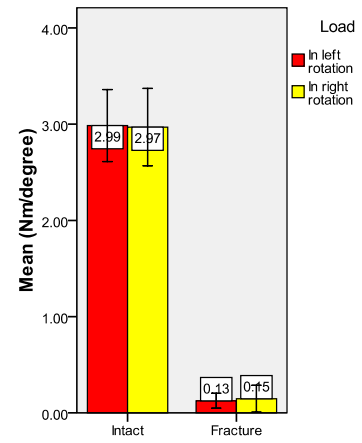
The comparison of the shear stiffness between the intact odontoid and after 2-FCS fixation in Group B



Graph 9

Error bars: +/- 1 SD

The comparison of the torsional stiffness between the intact odontoid and after 2-FCS fixation in Group B



Graph 10

Error bars: +/- 1 SD

IV. Discussion

4.1 Literature Survey

There are very few biomechanical studies that focus on comparing the biomechanical specialities of one-screw anterior fixation with that of two-screw fixation for type II odontoid fracture.

Graziano et al(38) and Sasso et al(90) published their study in 1993. Graziano et al(38) divided 8 fresh C1-C2 specimens into two groups and simulated Type II fractures by osteotomy. All the specimens were fixed using one or two 3.5mm cannulated bone screws. In order to account for possible variations in specimen quality as related to bone density and fracture configuration, the torsional and bending stiffness obtained for each specimen was divided by the corresponding stiffness obtained for wire fixation of that specimen. They concluded that one- or two-screw fixation offers similar stability for odontoid fracture fixation. Sasso et al(90) used 13 fresh C2 vertebrae and divided the specimens into three groups. Stiffness and failure load were used to compare the stability of type II odontoid fracture fixed with one or two 3.5mm AO cortical screws. No significant difference was concluded in extension loading and load-to-failure tests between the two fixation methods. They considered that their results support the clinical use of the one-screw technique. In 1995, McBride et al(65) reported a study using 12 specimens (10 embalmed and 2 fresh C2) to determine the stability of two- versus one-screw fixation technique for Type II odontoid fractures. Six specimens were stabilized with two 3.5mm cannulated AO screws, and the remainders were stabilized with a single 4.5mm cannulated Herbert screw. The biomechanical properties of the one 4.5mm cannulated Herbert screw fixation suggested, it may provide superior fixation of Type II odontoid fractures.

But all of these published studies had serious flaws in the study design. It is hard to draw the conclusion that one-screw fixation provides similar/more stability for odontoid fracture fixation compared to two-screw fixation. Graziano et al(38) used the C1-C2 specimens for the experiment during the study. It meant, that the alar ligaments, mainly transmitting torque on odontoid, had been cut out. In this condition, the torque load on C1 was not transmitted to the odontoid and screws because it was mainly resisted by the capsules of

the facet joints, the anterior longitudinal ligament and the tectorial membrane, which do not attach to the odontoid. The key point of anterior screw technique gaining rigid fixation for odontoid fracture, is the generation of high compressive forces between the fracture fragments by the screw. But the cortical screw used by Sasso et al(90) can not produce this biomechanical effect by itself. Shear stiffness and torque stiffness in different directions, especially the torque stiffness standing for the ability of countering the rotation between fracture fragments, are very important to explain whether there is significant different stabilization between one- and two-screw fixation. But Sasso et al(90) did not test torque stiffness. The quality of the bone affects the holding strength of the screw in bone.(28, 43, 101) McBride et al(65) and Sasso et al(90) did not consider the quality of the bone in their research work. In order to account for possible variations in specimen quality as related to bone density, the stiffness of the specimen fixed by screw was divided by the stiffness of the same specimen fixed by wire in Graziano's study(38). But this method was not logical. McBride et al(65) used two different types of screws with different diameters. As we know, different types of screws with different structure, mean that the biomechanical characteristics are absolutely different.

4.2 Comparison of Own Research with Previous Research

4.2.1 The Torque endured by the Odontoid in Normal Physiologic Conditions

As the keystone and the pivot at the C0-C1-C2, the odontoid resists the torque transmitted by the ligaments during rotation movement in normal physiologic conditions. So the torque transmitted to the odontoid by ligaments is a very important parameter for biomechanical studies. But the parameter can not be found from literature. For the development of a biomechanical model to investigate the ability of anti-torsion for different anterior fixation structures, we designed the preliminary examination and investigated the rotational ROM of C0-C2 and the corresponding torque transmitted to the odontoid in normal physiologic rotation.

Some groups (36, 75, 76, 78) have documented the load-displacement data of the intact ligamentous specimens in the physiologic ROM. They found that relatively small loads

produced large rotations across the complex. It is reported (76, 77) that 1.5Nm appeared to be a good approximation to the maximum physiological load, since the displacements increased not more than 5% (on the average) of the displacements at 1.0Nm. The load of 1.5Nm also was judged to be sufficient to produce physiologic motions but small enough to not injure the spine specimen.(78) Many studies on the upper cervical spine movement use the maximum moment 1.5Nm.(15, 72, 75, 78, 85) So we applied 1.5Nm to the specimens to investigate the maximum physiologic rotational ROM. The ROM measurements at 0.3 Nm and 1.5Nm correlated well to the data from the literature.(35, 77) We therefore concluded that the test device could be run effectively for our objective.

Higher torques (1.5Nm) increased the reduction ratio of the transmitted torque between the measurements with cut and with intact ligaments. We suppose, that the torque acting on the C0-C1-C2 is dominated by the ligaments which attach to the odontoid at smaller rotational angles with lower torque. At larger rotational angles with higher torque, the other ligaments that do not attach to the odontoid, will join in and react against the torque more. Especially the tension of fibres in the facets capsules reacts in larger angles, whereas in smaller angles flaccidly fibres had only a minimal resistance on torque.

4.2.2 The Influence of BMD

The BMD, one of the important quantitative parameters about the quality of the bone, was considered for its influence on the holding ability of screw in bone.(28, 43, 101) Some groups reported complications after anterior screw fixation for odontoid fractures due to osteopenic bone.(2) From the literature we know, that the quality of bone is not uniform in the C2 vertebra. The highest is found at the tip of the odontoid, the very low bone density area is consistently observed in the junction area of odontoid process and the middle part located in the corpus of the C2. The anteroinferior site always has a good cortical bone.(4, 34, 47) Anterior odontoid screws obtain strong fixation at their entrance site (the anteroinferior aspect of the C2 body) and exit site (the tip of the dens) but have relatively poor holding strength through the very weak hypodense bone in the body of C2. It suggests that fixation devices inserted through this area may be prone to cut-through failure.(47) The No. 1600 specimen (Age: 97 years) was just cut by the FCS at this area. So we tested

the BMD of the three points on each specimen: on the tip, on the base of the odontoid and on the anteroinferior part of the C2 body. The mean BMD of the three point was designated the BMD of the specimen.

4.2.3 Screw Selected

By now, there is no verdict what kind of screw is the best for odontoid fracture fixation. There is also no generally accepted standard of selecting screw for type II odontoid fracture. Many different types of screws are used for type II odontoid fractures, including cortical(24, 54) or cancellous bone screws(2, 26); Herbert screws(12, 26, 61) or Knöringer double-threaded screws(9); fully(24, 54) or partially threaded screws(12, 26, 50, 96); lag screws(6, 26, 54, 98) or cannulated screws(2, 26, 27, 30, 61, 81, 96); self-tapping(24, 27, 50) or nonself-tapping screws(54, 96, 98), and so on. The material of the screws is stainless steel or titanium(24, 96, 98). The diameter of the screws are 2.7mm(24), 3.0mm(12), 3.5mm(26, 27, 50, 54, 82), 4.0mm(2, 96) or even 4.5mm(2, 12, 26, 50, 61).

Different kinds of screws have different structures with different biomechanical properties. Based on the aims of our study, we must apply screws with the same structure. The entry point for the screw, lying at the anterior aspect of the inferior endplate of C2, make the screw head locating at the C2/C3 disc.(24, 50) The screw head has the potential to encroach on the C2/C3 disc, impact against with C3 vertebral body and produce discomfort and/or secondary degeneration due to the normal cervical movement after the operation.(24, 57) Anterior osteophyte formation at the anteroinferior border of C2, spontaneous anterior and posterior fusion and chronic neck pain have been found after anterior screw fixation.(24) It is better that the material of the screw has good biological compatibility and permit MRI examination. This technique achieves rigid fixation through the generation of high compressive forces across the fracture by screw. So the screw must have the ability of producing compression between the two fracture fragments.

The FCS used in the study has been applied to treat the type II odontoid fracture in the clinical setting of the University Medical Center Schleswig-Holstein. It is a double-threaded, headless, cannulated, self-tapping and self-drilling titanium screw. The double-threaded structure with different gradient and pitch, the finer pitch of the proximal

end and the wider pitch at the distal end, produces compression between fracture fragments after the distal end passing across the fracture line and the proximal thread entering the proximal bone fragment, draws the two bone fragments together during the insertion of the FCS. The double-threaded design not only produces better holding strength to the bone fragments but also assures that the proximal end is buried inside the bone and will not disturb the C2/3 disc during normal movement after bone healing. Since the distal thread has a diameter of 3.0 mm (with a core diameter of 2.0mm), and the proximal thread has a diameter of 4.0 mm (with a core diameter of 2.9mm), both threads can cut without interfering with each other during the insertion.

4.2.4 The Design and the Method for Evaluation of the Stability in this Study

The mechanism of type II odontoid fracture is not definitively understood in vivo up to now. Some groups succeed in producing type II-like odontoid fractures with lateral and oblique loading.(3) There is undoubtedly a variety of subtypes of the type II odontoid fractures related to different styles of the load and individual anatomic variation.

Two methods of simulating type II odontoid fracture in vitro were reported in the literature. One is to create a transverse osteotomy using oscillating saw at the base of the odontoid.(64) Another is to reproducibly form a type II fracture by direct 45° oblique extension loading of the anterior articular surface of the odontoid process.(90) In order to produce all the fracture models and the test conditions as same as possible, an osteotomy with a thin saw by hand was performed to simulate a Type II fracture pattern in our study. By this way, there was less bone loss at the fracture sites and the fracture patterns of all the specimens were exactly the same.

Only a small number of biomechanical investigations of the one- or two-screw fixation for type II odontoid fracture have been published.(19, 38, 64, 65, 90) One potential criticism of these studies was the stiffness was tested under only one or few directions load. We think this can not truly represent the stiffness after screw fixation, because the fixation structure has to resist multidirectional forces before bone union. The screw was inserted into the bone obliquely in sagittal plane; mostly it could not just put through the midline in coronal plane and the thread of the screw has its own direction. So the stiffness of different

directions must be different from each other. The stiffness of the odontoid was tested in six directions in this study and this hypothesis was confirmed by the test results.

4.3 Critical Integration of Own Results and Conclusions

1. The ROM measurements at 0.3 Nm and 1.5Nm correlated well to the data collected from literature research. The whole group was assigned randomly into Group A and Group B. There was no statistically significant difference in mean donor age, BMD and the stiffness of intact specimens in six directions between the two groups. All of the results showed the device could efficiently run for the research and the two groups based on a same test conditions. The results were reliable for the objective of the study.
2. In maximum physiologic rotational ROM, the torque load transmitted to the odontoid by ligaments is around 1/3 ($0.53 \pm 0.38 \text{ Nm}$) of the maximum physiological load (1.5 Nm) in axial rotation.
3. The torque acting on the C0-C2 is dominated by the odontoid at smaller rotational angles with lower torque. At larger rotational angles with higher torque, the other ligaments that do not attach to the odontoid will join in and react against the torque more. This biomechanical characteristic has to be considered in the evaluation of the one- or two-screw fixation for type II odontoid fracture experiment because the ligaments attaching to the odontoid are intact in this situation.
4. The BMD has statistical significant correlation with SA, SP, TL and TR of intact specimen except SL and SR in the whole group. There is no statistical significant correlation with the stiffness loading from six directions after FCS fixation (including one- and two-FCS fixation) except SP after two-FCS fixation. (The mean BMD of the whole group, the Group A and the Group B were $410.51 \pm 247.65 \text{ mg/cm}^2$, $477.27 \pm 255.63 \text{ mg/cm}^2$ and $343.74 \pm 239.02 \text{ mg/cm}^2$ individually.)
5. Both by one- and two-FCS fixation technique for type II odontoid fracture, the same shear and torsional stiffness can be gained. The result indicates that anterior odontoid fixation with one- or two-FCS offers similar stability.
6. Both one- or two-FCS fixation for type II odontoid fracture can not restore the normal

shear and torsional stiffness. The stiffness of the odontoid after one- or two-FCS fixation is much less compared to the uninjured odontoid.

7. In clinic, only collar immobilization is used after anterior screw fixation for type II odontoid fracture. It might be that the collar is not stable enough to immobilize the C0-C2. Though the rotational range of motion is less than normal after collar immobilization, the torque load transmitted by the ligaments attaching to the odontoid still plays an important role and should be considered in the biomechanical research for the very lower torsional stiffness after FCS fixation. The results of the research showed the FCS really functions more as a reduction mechanism. We suggest that combining with rigid postoperative immobilization after FCS fixation until the bone union makes the ultimate material strength and stiffness less critical.

V. Summary

The type II odontoid fracture is the most common type of odontoid fracture. It is inherently unstable because the odontoid is the keystone as well as the pivot of the craniovertebral junction. Anterior screw fixation is the best treatment for type II odontoid fracture. Both one- and two-screw techniques have their own merits and demerits. The objective of current study is to compare the stabilization between one- and two-screw fixation. 14 fresh axes were randomly divided into two groups and fixed with one- or two-screw respectively. The stiffness of intact specimens and after screw fixation in six directions was tested on the universal mechanical testing machine and the corresponding data compared with each other. In order to further analyze the stiffness, the torque transmitted by the ligaments during rotation movement was tested using 5 Fresh occipito-altanto-axial complexes. The influence by bone mineral density was also analyzed in the study. The results showed that the torque load transmitted to the odontoid by ligaments is around 1/3 ($0.53 \pm 0.38 \text{Nm}$) of the maximum physiological load (1.5Nm) in axial rotation. The torque acting on the occipito-altanto-axial complexes is dominated by the odontoid at smaller rotational angles. At larger rotational angles, the other ligaments that do not attach to the odontoid will join in and react against the torque more. The bone mineral density has statistical significant correlation with shear stiffness loading from anterior and posterior, torsional stiffness loading from left and right of intact specimen. Both one- and two-screw fixation for type II odontoid fracture can gain the same shear and torsional stiffness. The result indicates that anterior odontoid fixation with one- or two-screw offers similar stability. Both the techniques can not restore the normal shear and torsional stiffness. The stiffness of the odontoid after one- or two-FCS fixation is much less than that of normal.

VI. References

1. Adams VI: Neck injuries: II. Atlantoaxial dislocation--a pathologic study of 14 traffic fatalities. **J Forensic Sci** 37:565-573, 1992.
2. Aebi M, Etter C, Coscia M: Fractures of the odontoid process. Treatment with anterior screw fixation. **Spine** 14:1065-1070, 1989.
3. Althoff B: Fracture of the odontoid process. An experimental and clinical study. **Acta Orthop Scand Suppl** 177:1-95, 1979.
4. Amling M, Hahn M, Wening VJ, Grote HJ, Delling G: The microarchitecture of the axis as the predisposing factor for fracture of the base of the odontoid process. A histomorphometric analysis of twenty-two autopsy specimens. **J Bone Joint Surg Am** 76:1840-1846, 1994.
5. Anderson LD, D'Alonzo RT: Fractures of the odontoid process of the axis. **J Bone Joint Surg Am** 56:1663-1674, 1974.
6. Apfelbaum RI, Lonser RR, Veres R, Casey A: Direct anterior screw fixation for recent and remote odontoid fractures. **J Neurosurg** 93:227-236, 2000.
7. Arand M, Lemke M, Kinzl L, Hartwig E: [Incidence of complications of the screw osteosynthesis of odontoid process fractures]. **Zentralbl Chir** 126:610-615, 2001.
8. Bohler J: Anterior stabilization for acute fractures and non-unions of the dens. **J Bone Joint Surg Am** 64:18-27, 1982.
9. Borm W, Kast E, Richter HP, Mohr K: Anterior screw fixation in type II odontoid fractures: is there a difference in outcome between age groups? **Neurosurgery** 52:1089-1092; discussion 1092-1084, 2003.
10. Brooks AL, Jenkins EB: Atlanto-axial arthrodesis by the wedge compression method. **J Bone Joint Surg Am** 60:279-284, 1978.
11. Bucholz RW, Burkhead WZ, Graham W, Petty C: Occult cervical spine injuries in fatal traffic accidents. **J Trauma** 19:768-771, 1979.
12. Chang KW, Liu YW, Cheng PG, Chang L, Suen KL, Chung WL, Chen UL, Liang PL: One Herbert double-threaded compression screw fixation of displaced type II odontoid fractures. **J Spinal Disord** 7:62-69, 1994.
13. Clark CR, White AA, 3rd: Fractures of the dens. A multicenter study. **J Bone Joint Surg Am** 67:1340-1348, 1985.
14. Collins I, Min WK: Anterior screw fixation of type II odontoid fractures in the elderly. **J Trauma** 65:1083-1087, 2008.
15. Crawford NR, Hurlbert RJ, Choi WG, Dickman CA: Differential biomechanical effects of injury and wiring at C1-C2. **Spine** 24:1894-1902, 1999.
16. Crockard HA, Heilman AE, Stevens JM: Progressive myelopathy secondary to odontoid fractures: clinical, radiological, and surgical features. **J Neurosurg** 78:579-586, 1993.
17. Davis D, Bohlman H, Walker AE, Fisher R, Robinson R: The pathological findings in fatal craniospinal injuries. **J Neurosurg** 34:603-613, 1971.
18. Della Torre P, Fiacca C, Lignini S: An evaluation of the results of two non-surgical methods in the treatment of fractures of the odontoid process. **Chir Organi Mov** 85:45-52, 2000.
19. Doherty BJ, Heggeness MH, Esses SI: A biomechanical study of odontoid fractures and fracture fixation. **Spine** 18:178-184, 1993.
20. Dunn ME, Seljeskog EL: Experience in the management of odontoid process injuries: an analysis of

- 128 cases. **Neurosurgery** 18:306-310, 1986.
21. Dvorak J, Panjabi MM: Functional anatomy of the alar ligaments. **Spine** 12:183-189, 1987.
 22. Dvorak J, Schneider E, Saldinger P, Rahn B: Biomechanics of the craniocervical region: the alar and transverse ligaments. **J Orthop Res** 6:452-461, 1988.
 23. Ebraheim NA, Lu J, Yang H: The effect of translation of the C1-C2 on the spinal canal. **Clin Orthop Relat Res**:222-229, 1998.
 24. ElSaghir H, Bohm H: Anderson type II fracture of the odontoid process: results of anterior screw fixation. **J Spinal Disord** 13:527-530; discussion 531, 2000.
 25. Ersmark H, Kalen R: Injuries of the atlas and axis. A follow-up study of 85 axis and 10 atlas fractures. **Clin Orthop Relat Res**:257-260, 1987.
 26. Esses SI, Bednar DA: Screw fixation of odontoid fractures and nonunions. **Spine** 16:S483-485, 1991.
 27. Etter C, Coscia M, Jaberg H, Aebi M: Direct anterior fixation of dens fractures with a cannulated screw system. **Spine** 16:S25-32, 1991.
 28. Eysel P, Schwitalle M, Oberstein A, Rompe JD, Hopf C, Kullmer K: Preoperative estimation of screw fixation strength in vertebral bodies. **Spine (Phila Pa 1976)** 23:174-180, 1998.
 29. Fernyhough JC, Schimandle JJ, Weigel MC, Edwards CC, Levine AM: Chronic donor site pain complicating bone graft harvesting from the posterior iliac crest for spinal fusion. **Spine** 17:1474-1480, 1992.
 30. Fountas KN, Kapsalaki EZ, Karampelas I, Feltz CH, Dimopoulos VG, Machinis TG, Nikolakakos LG, Boev AN, 3rd, Choudhri H, Smisson HF, Robinson JS: Results of long-term follow-up in patients undergoing anterior screw fixation for type II and rostral type III odontoid fractures. **Spine** 30:661-669, 2005.
 31. Fujii E, Kobayashi K, Hirabayashi K: Treatment in fractures of the odontoid process. **Spine** 13:604-609, 1988.
 32. Gallie WE: Skeletal Traction in the Treatment of Fractures and Dislocations of the Cervical Spine. **Ann Surg** 106:770-776, 1937.
 33. Garfin SR, Botte MJ, Waters RL, Nickel VL: Complications in the use of the halo fixation device. **J Bone Joint Surg Am** 68:320-325, 1986.
 34. Gebauer M, Lohse C, Barvencik F, Pogoda P, Rueger JM, Puschel K, Amling M: Subdental synchondrosis and anatomy of the axis in aging: a histomorphometric study on 30 autopsy cases. **Eur Spine J** 15:292-298, 2006.
 35. Goel VK, Clark CR, Gallaes K, Liu YK: Moment-rotation relationships of the ligamentous occipito-atlanto-axial complex. **J Biomech** 21:673-680, 1988.
 36. Goel VK, Winterbottom JM, Schulte KR, Chang H, Gilbertson LG, Pudgil AG, Gwon JK: Ligamentous laxity across C0-C1-C2 complex. Axial torque-rotation characteristics until failure. **Spine** 15:990-996, 1990.
 37. Govender S, Maharaj JF, Haffajee MR: Fractures of the odontoid process. **J Bone Joint Surg Br** 82:1143-1147, 2000.
 38. Graziano G, Jagers C, Lee M, Lynch W: A comparative study of fixation techniques for type II fractures of the odontoid process. **Spine** 18:2383-2387, 1993.
 39. Greene KA, Dickman CA, Marciano FF, Drabier JB, Hadley MN, Sonntag VK: Acute axis fractures. Analysis of management and outcome in 340 consecutive cases. **Spine** 22:1843-1852, 1997.
 40. Hadley MN, Browner C, Sonntag VK: Axis fractures: a comprehensive review of management and

- treatment in 107 cases. **Neurosurgery** 17:281-290, 1985.
41. Hadley MN, Browner CM, Liu SS, Sonntag VK: New subtype of acute odontoid fractures (type IIA). **Neurosurgery** 22:67-71, 1988.
 42. Hadley MN, Sonntag VK, Grahm TW, Masferrer R, Browner C: Axis fractures resulting from motor vehicle accidents. The need for occupant restraints. **Spine** 11:861-864, 1986.
 43. Halvorson TL, Kelley LA, Thomas KA, Whitecloud TS, 3rd, Cook SD: Effects of bone mineral density on pedicle screw fixation. **Spine (Phila Pa 1976)** 19:2415-2420, 1994.
 44. Hanssen AD, Cabanela ME: Fractures of the dens in adult patients. **J Trauma** 27:928-934, 1987.
 45. Harms J, Melcher RP: Posterior C1-C2 fusion with polyaxial screw and rod fixation. **Spine** 26:2467-2471, 2001.
 46. Harrop JS, Sharan AD, Przybylski GJ: Epidemiology of spinal cord injury after acute odontoid fractures. **Neurosurg Focus** 8:e4, 2000.
 47. Heggeness MH, Doherty BJ: The trabecular anatomy of the axis. **Spine** 18:1945-1949, 1993.
 48. Heinzelmann M, Eid K, Boos N: Cervical spine injuries, in Boos N, Aebi M (eds): *Spinal disorders fundamentals of diagnosis and treatment*. Berlin, Springer berlin heidelberg, 2008, pp 825-881.
 49. Heller JG, Alson MD, Schaffler MB, Garfin SR: Quantitative internal dens morphology. **Spine** 17:861-866, 1992.
 50. Henry AD, Bohly J, Grosse A: Fixation of odontoid fractures by an anterior screw. **J Bone Joint Surg Br** 81:472-477, 1999.
 51. Horn EM, Theodore N, Feiz-Erfan I, Lekovic GP, Dickman CA, Sonntag VK: Complications of halo fixation in the elderly. **J Neurosurg Spine** 5:46-49, 2006.
 52. Huelke DF, O'Day J, Mendelsohn RA: Cervical injuries suffered in automobile crashes. **J Neurosurg** 54:316-322, 1981.
 53. Jeanneret B, Magerl F: Primary posterior fusion C1/2 in odontoid fractures: indications, technique, and results of transarticular screw fixation. **J Spinal Disord** 5:464-475, 1992.
 54. Jeanneret B, Vernet O, Frei S, Magerl F: Atlantoaxial mobility after screw fixation of the odontoid: a computed tomographic study. **J Spinal Disord** 4:203-211, 1991.
 55. Jenkins JD, Coric D, Branch CL, Jr.: A clinical comparison of one- and two-screw odontoid fixation. **J Neurosurg** 89:366-370, 1998.
 56. Julien TD, Frankel B, Traynelis VC, Ryken TC: Evidence-based analysis of odontoid fracture management. **Neurosurg Focus** 8:e1, 2000.
 57. Knoringer P: Osteosynthesis of injuries and rheumatic or congenital instabilities of the upper cervical spine using double-threaded screws. **Neurosurg Rev** 15:275-283, 1992.
 58. Koch RA, Nickel VL: The halo vest: an evaluation of motion and forces across the neck. **Spine** 3:103-107, 1978.
 59. Koivikko MP, Kiuru MJ, Koskinen SK, Myllynen P, Santavirta S, Kivisaari L: Factors associated with nonunion in conservatively-treated type-II fractures of the odontoid process. **J Bone Joint Surg Br** 86:1146-1151, 2004.
 60. Lakshmanan P, Jones A, Howes J, Lyons K: CT evaluation of the pattern of odontoid fractures in the elderly--relationship to upper cervical spine osteoarthritis. **Eur Spine J** 14:78-83, 2005.
 61. Lee SH, Sung JK: Anterior odontoid fixation using a 4.5-mm Herbert screw: The first report of 20 consecutive cases with odontoid fracture. **Surg Neurol** 66:361-366; discussion 366, 2006.
 62. Lind B, Bake B, Lundqvist C, Nordwall A: Influence of halo vest treatment on vital capacity. **Spine** 12:449-452, 1987.

63. Maak TG, Grauer JN: The contemporary treatment of odontoid injuries. **Spine** 31:S53-60; discussion S61, 2006.
64. Magee W, Hettwer W, Badra M, Bay B, Hart R: Biomechanical comparison of a fully threaded, variable pitch screw and a partially threaded lag screw for internal fixation of Type II dens fractures. **Spine** 32:E475-479, 2007.
65. McBride AD, Mukherjee DP, Kruse RN, Albright JA: Anterior screw fixation of type II odontoid fractures. A biomechanical study. **Spine** 20:1855-1859; discussion 1859-1860, 1995.
66. Montesano PX, Anderson PA, Schlehr F, Thalgott JS, Lowrey G: Odontoid fractures treated by anterior odontoid screw fixation. **Spine** 16:S33-37, 1991.
67. Moon MS, Moon JL, Sun DH, Moon YW: Treatment of dens fracture in adults: A report of thirty-two cases. **Bull Hosp Jt Dis** 63:108-112, 2006.
68. Morandi X, Hanna A, Hamlat A, Brassier G: Anterior screw fixation of odontoid fractures. **Surg Neurol** 51:236-240, 1999.
69. Moskovich R, Crockard HA: Myelopathy due to hypertrophic nonunion of the dens: case report. **J Trauma** 30:222-225, 1990.
70. Mouradian WH, Fietti VG, Jr., Cochran GV, Fielding JW, Young J: Fractures of the odontoid: a laboratory and clinical study of mechanisms. **Orthop Clin North Am** 9:985-1001, 1978.
71. Muller EJ, Wick M, Russe O, Muhr G: Management of odontoid fractures in the elderly. **Eur Spine J** 8:360-365, 1999.
72. Naderi S, Crawford NR, Song GS, Sonntag VK, Dickman CA: Biomechanical comparison of C1-C2 posterior fixations. Cable, graft, and screw combinations. **Spine** 23:1946-1955; discussion 1955-1946, 1998.
73. Nakanishi T: Internal fixation of the odontoid fracture. **Cent J Orthop Trauma Surg** 23:399-406, 1980.
74. Nucci RC, Seigal S, Merola AA, Gorup J, Mroczek KJ, Dryer J, Zipnick RI, Hafer TR: Computed tomographic evaluation of the normal adult odontoid. Implications for internal fixation. **Spine** 20:264-270, 1995.
75. Oda T, Panjabi MM, Crisco JJ, 3rd: Three-dimensional translational movements of the upper cervical spine. **J Spinal Disord** 4:411-419, 1991.
76. Panjabi M, Dvorak J, Crisco J, 3rd, Oda T, Hilibrand A, Grob D: Flexion, extension, and lateral bending of the upper cervical spine in response to alar ligament transections. **J Spinal Disord** 4:157-167, 1991.
77. Panjabi M, Dvorak J, Crisco JJ, 3rd, Oda T, Wang P, Grob D: Effects of alar ligament transection on upper cervical spine rotation. **J Orthop Res** 9:584-593, 1991.
78. Panjabi M, Dvorak J, Duranceau J, Yamamoto I, Gerber M, Rauschnig W, Bueff HU: Three-dimensional movements of the upper cervical spine. **Spine** 13:726-730, 1988.
79. Panjabi MM, Crisco JJ, Vasavada A, Oda T, Cholewicki J, Nibu K, Shin E: Mechanical properties of the human cervical spine as shown by three-dimensional load-displacement curves. **Spine** 26:2692-2700, 2001.
80. Pepin JW, Bourne RB, Hawkins RJ: Odontoid fractures, with special reference to the elderly patient. **Clin Orthop Relat Res**:178-183, 1985.
81. Platzer P, Thalhammer G, Oberleitner G, Schuster R, Vecsei V, Gaebler C: Surgical treatment of dens fractures in elderly patients. **J Bone Joint Surg Am** 89:1716-1722, 2007.
82. Platzer P, Thalhammer G, Ostermann R, Wieland T, Vecsei V, Gaebler C: Anterior screw fixation of

- odontoid fractures comparing younger and elderly patients. **Spine** 32:1714-1720, 2007.
83. Polin RS, Szabo T, Bogaev CA, Replogle RE, Jane JA: Nonoperative management of Types II and III odontoid fractures: the Philadelphia collar versus the halo vest. **Neurosurgery** 38:450-456; discussion 456-457, 1996.
 84. Przybylski GJ, Harrop JS, Vaccaro AR: Closed management of displaced Type II odontoid fractures: more frequent respiratory compromise with posteriorly displaced fractures. **Neurosurg Focus** 8:e5, 2000.
 85. Puttlitz CM, Melcher RP, Kleinstueck FS, Harms J, Bradford DS, Lotz JC: Stability analysis of craniovertebral junction fixation techniques. **J Bone Joint Surg Am** 86-A:561-568, 2004.
 86. Rao G, Apfelbaum RI: Odontoid screw fixation for fresh and remote fractures. **Neurol India** 53:416-423, 2005.
 87. Richter D, Latta LL, Milne EL, Varkarakis GM, Biedermann L, Ekkernkamp A, Ostermann PA: The stabilizing effects of different orthoses in the intact and unstable upper cervical spine: a cadaver study. **J Trauma** 50:848-854, 2001.
 88. Rudzki JR, Lenke LG, Blanke K, Riew KD: Pseudarthrosis of a thirty-nine-year-old dens fracture causing myelopathy. A case report. **J Bone Joint Surg Am** 86-A:2509-2513, 2004.
 89. Sanchez Martin MM: Occipital-cervical instability. **Clin Orthop Relat Res**:63-73, 1992.
 90. Sasso R, Doherty BJ, Crawford MJ, Heggeness MH: Biomechanics of odontoid fracture fixation. Comparison of the one- and two-screw technique. **Spine** 18:1950-1953, 1993.
 91. Sasso RC: C2 dens fractures: treatment options. **J Spinal Disord** 14:455-463, 2001.
 92. Schaffler MB, Alson MD, Heller JG, Garfin SR: Morphology of the dens. A quantitative study. **Spine** 17:738-743, 1992.
 93. Schatzker J, Rorabeck CH, Waddell JP: Fractures of the dens (odontoid process). An analysis of thirty-seven cases. **J Bone Joint Surg Br** 53:392-405, 1971.
 94. Scott EW, Haid RW, Jr., Peace D: Type I fractures of the odontoid process: implications for atlanto-occipital instability. Case report. **J Neurosurg** 72:488-492, 1990.
 95. Seybold EA, Bayley JC: Functional outcome of surgically and conservatively managed dens fractures. **Spine** 23:1837-1845; discussion 1845-1836, 1998.
 96. Shilpakar S, McLaughlin MR, Haid RW, Jr., Rodts GE, Jr., Subach BR: Management of acute odontoid fractures: operative techniques and complication avoidance. **Neurosurg Focus** 8:e3, 2000.
 97. Strohm PC, Bley TA, Ghanem N, Scheck B, Sudkamp NP, Muller Ch A: Clinical and radiological findings after different treatment of odontoid fractures type Anderson II and III. **Acta Chir Orthop Traumatol Cech** 73:151-156, 2006.
 98. Subach BR, Morone MA, Haid RW, Jr., McLaughlin MR, Rodts GR, Comey CH: Management of acute odontoid fractures with single-screw anterior fixation. **Neurosurgery** 45:812-819; discussion 819-820, 1999.
 99. Tubbs RS, Salter EG, Oakes WJ: The accessory atlantoaxial ligament. **Neurosurgery** 55:400-402; discussion 402-404, 2004.
 100. Whitehill R, Richman JA, Glaser JA: Failure of immobilization of the cervical spine by the halo vest. A report of five cases. **J Bone Joint Surg Am** 68:326-332, 1986.
 101. Wittenberg RH, Shea M, Swartz DE, Lee KS, White AA, 3rd, Hayes WC: Importance of bone mineral density in instrumented spine fusions. **Spine (Phila Pa 1976)** 16:647-652, 1991.
 102. Younger EM, Chapman MW: Morbidity at bone graft donor sites. **J Orthop Trauma** 3:192-195, 1989.

VII Attachments

Table 1. Gender, Age and Bone Mineral Density (BMD) of Specimens

See page 18

Table 2. The ROM of C0-C1-C2 and the torque applied to odontoid under 0.3Nm and 1.5Nm

No.	0.3Nm				1.5Nm			
	Angle (degree)		Torque (Nm)		Angle (degree)		Torque (Nm)	
	Left	Right	Left	Right	Left	Right	Left	Right
1599	32.11	19.42	0.16	0.08	38.90	25.47	0.27	0.14
1601	27.44	6.84	0.18	0.14	37.72	15.82	0.68	0.39
1603	22.18	34.50	0.16	0.20	29.98	45.54	0.46	0.41
1614	32.36	12.75	0.29	0.27	45.67	23.89	1.46	0.81
1623	31.39	32.34	0.11	0.12	43.11	38.82	0.34	0.34
mean±SD	25.13±9.51		0.17±0.07		34.49±10.18		0.53±0.38	

Table 3. The correlations between the BMD and the stiffness of intact specimens, the stiffness after FCS fixation in six directions

		SA	SL	SP	SR	TL	TR
Intact	Whole Group	$r=0.608$, $P<0.05^{\#}$	$r=0.124$, $P>0.05$	$r=0.672$, $P<0.05^{\#}$	$r=0.416$, $P>0.05$	$r=0.728$, $P<0.05^{\#}$	$r=0.658$, $P<0.05^{\#}$
After FCS Fixation	Group A	$r=0.320$, $P>0.05$	$r=0.264$, $P>0.05$	$r=0.223$, $P>0.05$	$r=0.141$, $P>0.05$	$r=-0.181$, $P>0.05$	$r=-0.193$, $P>0.05$
	Group B	$r=0.452$, $P>0.05$	$r=0.605$, $P>0.05$	$r=0.817$, $P<0.05^{\#}$	$r=0.285$, $P>0.05$	$r=0.097$, $P>0.05$	$r=-0.011$, $P>0.05$

[#]. Pearson correlation is significant at the 0.05 level (2-tailed).

Table 4. The Shear Stiffness of Intact Specimens

(N/mm)

Group A					Group B				
No.	SA	SL	SP	SR	No.	SA	SL	SP	SR
1600	684.13	2765.74	307.84	1797.43	1599	646.85	1290.01	626.44	1669.24
1603	2427.42	7250.21	3966.88	1697.08	1601	1547.55	736.62	1782.03	3851.65
1617	4447.95	4262.28	3802.35	33495.64	1605	1686.73	4715.59	1645.07	2516.13
1623	2013.81	3105.43	1455.26	6412.71	1614	894.20	7308.05	673.34	2783.28
1644	427.57	2850.16	378.18	1781.87	1620	730.38	5711.53	668.54	2116.73
1647	1349.27	3021.71	2071.56	3503.31	1631	640.94	926.95	653.59	2029.16
1648	1247.46	2268.09	687.40	1784.37	1649	1178.28	1656.36	1844.41	2984.98
mean	1799.66	3646.23	1809.93	2829.46	mean	1046.42	3192.16	1127.63	2564.45
±	±	±	±	±	±	±	±	±	±
SD	1359.42	1700.93	1548.26	1888.43	SD	433.14	2669.15	592.00	727.13
The mean shear stiffness of the whole group: SA 1423.04±1045.12 SL 3419.20±2163.10 SP 1468.78±1180.44 SR 2686.76±1330.10									

Table 5. The Torsional Stiffness of Intact Specimens

(Nm/degree)

Group A			Group B		
No.	TL	TR	No.	TL	TR
1600	1.54	1.46	1599	2.33	2.49
1603	4.55	3.71	1601	3.45	3.50
1617	5.88	6.44	1605	3.16	3.06
1623	2.63	2.44	1614	3.18	2.73
1644	3.14	3.31	1620	3.00	3.45
1647	4.59	4.18	1631	2.66	2.57
1648	2.06	2.19	1649	3.12	2.99
mean±SD	3.48±1.57	3.39±1.64	mean±SD	2.99±0.37	2.97±0.40
The mean torsional stiffness of the whole group: TL 3.24±1.13 TR 3.18±1.17					

Table 6. The Shear Stiffness of Specimens after FCS fixation

(N/mm)

Group A					Group B				
No.	SA	SL	SP	SR	No.	SA	SL	SP	SR
1600	90.98	000	000	000	1599	82.46	76.81	84.25	99.51
1603	1338.87	642.59	1222.41	906.22	1601	853.17	676.01	371.56	346.18
1617	385.97	260.72	227.33	239.16*	1605	387.74	523.49	359.64	620.44
1623	834.82	708.08	427.95	708.86	1614	345.63	522.40	200.94	488.84
1644	217.72	103.35	146.77	110.84	1620	814.63	402.18	259.37	699.10
1647	188.39	204.98	194.53	113.83	1631	139.90	115.60	103.66	71.53
1648	334.08	84.72	71.96	112.63	1649	135.05	393.87	223.62	442.99
mean	484.40	334.07	381.82	365.26	mean	394.08	387.19	229.01	395.51
±	±	±	±	±	±	±	±	±	±
SD	446.97	272.95	428.70	351.67	SD	321.15	220.09	112.39	241.09

Table 7. The Torsional Stiffness of Specimens after FCS fixation

(Nm/degree)

Group A			Group B		
No.	TL	TR	No.	TL	TR
1600	000	000	1599	0.06	0.05
1603	0.09	0.06	1601	0.13	0.20
1617	0.02	0.03	1605	0.15	0.13
1623	0.03	0.05	1614	0.24	0.40
1644	0.06	0.08	1620	000	0.08
1647	0.07	0.06	1631	0.05	0.02
1648	0.07	0.05	1649	000	000
mean±SD	0.057±0.027	0.055±0.016	Mean±SD	0.126±0.077	0.147±0.139

VIII Acknowledgements

I would like to take this opportunity to express my gratitude to the following people who have made the completion of the present thesis possible.

My heartfelt thanks first go to my supervisor Priv. Doz. Dr. med. Arndt Peter Schulz, who has offered many valuable comments and suggestions at every stage of my research work and thesis writing. He has taken great pains reading my drafts again and again and offered insightful comments and suggestions on the language and the overall structure as well.

I am also very grateful of Dr. med. Sebastian Spuck at the neurosurgery department, Dipl. -Ing. Robert Wendlandt at the biomechanical laboratory and Dr. rer. Pol. Reinhard Vonthein at the statistical department. They gave me much help in preparation for the research work, making the study plan, calculating and analyzing the data and have always been helpful whenever I needed academic advice. Their encouragement and insightful instruction have helped me during the progress of my MD thesis. I also owe thanks to the help of the following teachers and students at Luebeck University: Prof. Dr. rer. nat. Lüder C. Busch, Ms. Jana Maynicke, Ms. Nadine Teletzky at the anatomic department and Mr. Markus Heinritz, Mr. Jens Rose, Mr. Gregor Zachert at the biomechanical laboratory. From them, I have acquired technical assistance.

I also appreciate the kindnesses from Priv. Doz. Dr. med. Andreas Paech ,the head of trauma department, and Dr. med. O. J. Bisping, Dr. med. G. Heinrichs, Dr. med. J. Gille. They gave me much more convenience in clinic and daily routine.

I would also like to extend my gratitude to Ms. Marlin Maass at the international office and my friends who accompanied me during my stay in Luebeck. They have taken trouble in helping me and kept me staying in Germany pleasantly.

Last but not least, I would like to thank my family, my wife Min Zheng and my son Junhao Feng. Even in a very difficult situation, my father-in-law suddenly passed away, their persistent support has ensured the accomplishment of my study and this thesis.

IX Curriculum Vitae

Name: Gang Feng
Gender: Male
Date of Birth: January 18th, 1973
Place of Birth: Daqing, Heilongjiang Province, Peoples Republic of China

Education Experience

Sep. 1979-Jul. 1984 Elementary School of the First Hospital, Daqing
Heilongjiang Province, Peoples Republic of China
Sep. 1984-Jul. 1987 Junior High School of First Middle School, Daqing
Heilongjiang Province, Peoples Republic of China
Sep. 1987-Jul. 1990 Senior High School of First Middle School, Daqing
Heilongjiang Province, Peoples Republic of China
Sep. 1990-Jul. 1995 Bachelor Degree of Medicine
Harbin Medical University, Harbin
Heilongjiang Province, Peoples Republic of China
Sep. 1999-Jul. 2002 Master Degree in Orthopaedics
Zhejiang University School of Medicine, Hangzhou
Zhejiang Province, Peoples Republic of China
Oct. 2008-Oct. 2009 Guest scholar for a Research and Observation visit
Department of Trauma & Orthopaedics
University of Luebeck, Germany

Working Experience

Jul. 1995-Sep. 1999 Resident
General Hospital of Daqing Oil Field, Daqing
Heilongjiang Province, Peoples Republic of China
Sep. 2002- Present Attending and Associate Consultant Surgeon
Orthopaedic Department of 2nd Affiliated Hospital
Zhejiang University School of Medicine, Hangzhou
Zhejiang Province, Peoples Republic of China

